

Effect on Crude Oil on Intestinal Motility and Histology of Ileum of Wistar Rats

NAIHO ALEXANDER OBIDIKE

Department of Physiology Delta State University Abraka, Delta State (Nigeria).

(Received: January 01, 2012; Accepted: February 03, 2012)

ABSTRACT

Diesel exhaust is a common air pollutant made up of gases hydrocarbon and particles. This work examined the effect of liquid diesel on gastro-intestinal motility and histology of ileum. 18 female wistar rats were used for the experiment and divided into three; control group A, experimental group B and experiment group C. The group A was administered with Rat Chow and Water while, the group B and group C received 10mg/kg and 15mg/kg mixture of diesel and water respectively for a period of 21 days. The animals were weighed and sacrificed after an overnight fast and administration of activated charcoal meal. Results show it was observed that there was a non-significant ($p>0.05$) reduction in weight of the experimental groups compared to that of the control group. Group B (10mg/kg) and group C (15mg/kg) showed significant ($p<0.05$) increased in intestinal motility but between the two there was no significant ($p>0.05$) difference. In conclusion liquid diesel caused reduced weight and dose dependent increased GIT motility and adverse structural changes in the histology of the ileum. It is therefore advised that individuals should avoid ingestion of water contaminated with diesel.

Key words: Crude oil, Ileum, motility and Diesel.

INTRODUCTION

Diesel exhaust is a common air pollutant made up of gases hydrocarbon and particles, its effect on the intestine of fish have been documented (Brenniman 1979). In Nigeria, a large mass of surface water have been polluted by petroleum products including diesel. Since this surface water is the only source of drinking water to the inhabitants of the riverside communities of the Niger delta, these inhabitants may be exposed to hazardous effect of diesel. The major health threat of ingestion occurs from the danger of aspiration of liquid drops into the lungs particularly from vomiting. Aspiration may result in chemical pneumonia (fluids in lungs) severe lungs damage, respiratory failure and even death (Material safety data sheet 2006). Ingestion may also cause gastro-intestinal disturbances, including irritation, vomiting, and diarrhea and central nervous system effects similar to alcohol intoxication. In several cases tremors convulsions, loss of consciousness, coma,

respiratory arrest and death may occur (Material safety data sheet 2006). Workers exposed to diesel exhaust has been reported to have a prevalence of symptoms such as burning eyes, headache, difficult breathing (Gamble et al 1987); lungs cancers (McClellan 1987) Long term exposure has been related to decrease in lungs function in children (Bunkreef 1997) and adult (Ackermann 1997) and mutations in chromosomes and damage to DNA have been documented (Maudley 1992). It becomes imperative therefore to study the possible effect of oral ingestion of diesel on intestinal motility and histology of the ileum. This is important especially as the gastro-intestinal tract is essential for digestion and absorption of nutrient in order to meet energy requirement and general body metabolism for the maintenance of good health.

MATERIALS AND METHOD

Diesel was obtained from a local fuel station in Abraka Delta state Nigeria and activated

charcoal was obtained from a local pharmaceutical company.

Eighteen albino wistar rats were purchased from the animal house of the faculty of basic medical sciences, Ambrose Ali University, Ekpoma. The rats were housed in the animal house of the faculty of basic Medical science, Delta State University, Abraka, to acclimatize to housing conditions for two weeks prior to experiment.

Experimental Design

The rats were divided into three groups of six rats each. The control group A received rat chow and tap water ad libitum. The experimental animals in group B were exposed to diesel in their drinking water at a dose of 10mg/kg body weight while the experimental animals in group C were exposed to diesel in their drinking water at a dose of 15mg/kg body weight. Both experimental groups received rat chow ad libitum. Administration lasted for 21 days before experiment and harvest of tissues.

Experimental procedure

The animals in the control group and experimental groups were weighed to determine their terminal weights. Each animal was given 1.3ml of charcoal meal (5g activated charcoal mixed in 100ml of distilled water) orally after an overnight fast. After 30 minutes, each animal was sacrificed,

the gastrointestinal tract was extracted and the small intestine was stretched out and closely observed, the length of the small intestine of each animal was measured using a meter rule and the distance moved by the charcoal meal in the small intestine of each animal was measured and expressed as percentage of distance moved. At the end of the gastrointestinal motility test, a section of ileum of control and experimental animals was harvested. The harvested tissues were immediately preserved in 10% formalin in separate universal bottles bearing appropriate tags. The tissues were taken for histological analysis. Student's t test was used for data analysis.

RESULTS

Effect of Diesel On Body Weight

The effect of diesel on the body weight of rats was determined in this study. The body weight of the rats in control increased, the other groups (treatment groups) witnessed a reduction in weight.

In Table 1 the mean body weight of Control before treatment was 190.00 ± 17.89 and it increased to a mean weight of 223.33 ± 15.06 after treatment, the comparison between the initial weight and final weight showed a significant difference ($P > 0.05$).

Table 1: The effect of diesel on body weight of wistar rat

Groups	Initial Weight	Final weight
Group A (Control)	190.00 ± 17.89	$223.33 \pm 15.06^*$
Group B (10mg/ml)	200.00 ± 17.89	$167.50 \pm 13.32^*$
Group C (15mg/ml)	230.00 ± 20.98	185.00 ± 46.37

Values are presented as means \pm SD; *P < 0.05 compared with Pretest. (n=6)

Table 2: The effect of diesel on gastrointestinal tract motility

Parameters	GroupA (Control)	GroupB (10mg/ml)	GroupC (15mg/ml)
Length of ileum (mm)	86.75 ± 8.10	87.08 ± 7.34	99.20 ± 13.10
Distance covered (mm)	74.25 ± 11.93	74.00 ± 15.05	$89.8-0 \pm 18.58$
Motility (%)	85.23 ± 6.83	84.85 ± 14.75	$89.96. \pm 9.71$

Values are presented as means \pm SD; *P < 0.05 compared with control (n=6)

Conversely, Group B and C with initial mean level of body weight before treatment were 200.00 ± 17.89 and 230.00 ± 20.98 , but after treatment with 10mg/ml and 15mg/ml of diesel showed a reduction of mean weight to 167.50 ± 13.32 g and 185.00 ± 46.37 g respectively. 10mg/ml of diesel caused reduction in the body weight and there was a significant difference ($P > 0.05$). Despite the decrease in body weight caused by 15mg/ml of diesel, there was no significant difference.

the rats treated with 15mg/kg of diesel had increased the intestinal motility.

In the above table, the Group A (Control) with a mean ileum length of 86.75 ± 8.10 had a mean distance of 74.25 ± 11.93 covered, Group B had a mean ileum length of 87.08 ± 7.34 with distance moved by the activated charcoal 74.00 ± 15.05 while Group C with a mean ileum length of 99.20 ± 13.10 and distance moved by the activated charcoal was 89.80 ± 18.58 .

Effect of diesel on the gastrointestinal tract motility

In this study, the effect of diesel on the gastrointestinal tract motility was studied. The rats treated with 10mg/kg of diesel for 21 days had a non significant change in intestinal motility while

Group B rats had a reduced rate of motility when compared with control Group A, but was not statistically significant ($P > 0.05$). Group C rats when compared with control Group A showed an increase in the rate of intestinal motility which was however not significant difference ($P > 0.05$).

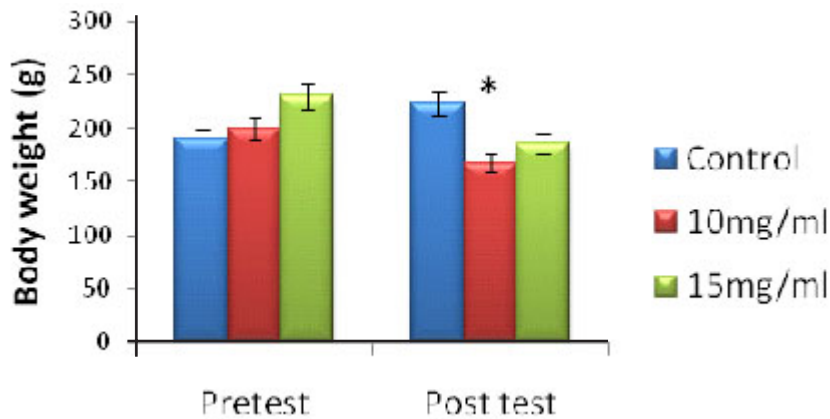


Fig 1: Effect of Diesel on Body weight

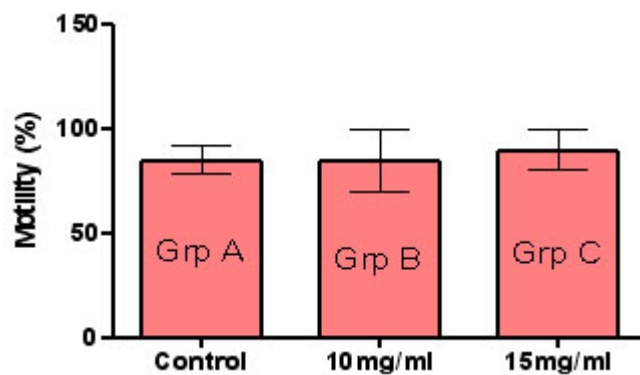


Fig 2: Effect of Diesel on Gastrointestinal motility(n=6); *P < 0.05 compared with control group;

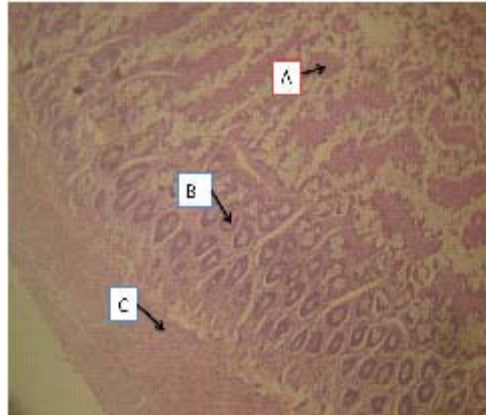
Histology of Rat Ileum

Plate 1: Control (untreated) rat ileum [H&E x100]. Photomicrograph show normal mucosal villi (A), Brunner's glands (B), muscularis externa (C) and intestinal gland (G).

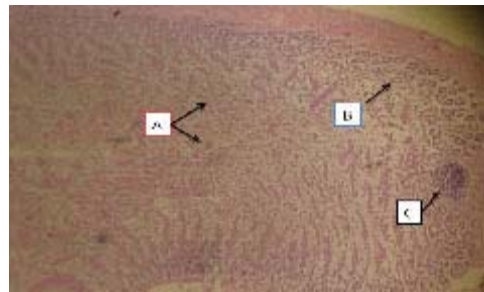


Plate 2: Micrograph of ileum of rats treated with 10mg/kg of diesel [H&E x10] showing severe degeneration of mucosal villi (A), without involving the Brunner's glands (B) and a normal lymphoid aggregate in the lamina propria (C).

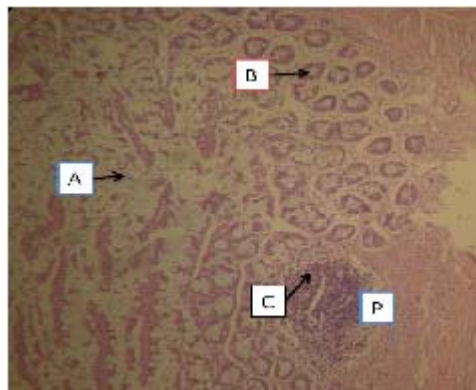


Plate 3: Micrograph of ileum of rats treated with 15mg/kg diesel [H&E x400] showing severe degeneration (atrophy) of mucosal villi (A), without involving the Brunner's glands (B) and a normal lymphoid aggregate in the lamina propria (C) and Payer's patches (P).

DISCUSSION

From the results obtained, it was discovered that there was a reduction in weight of experimental rats and a significant increase in gut motility of experimental rats. Experimental group B that received 0mg/kg of diesel did not show any significant difference in motility it has a slight mean level compared to that of the control group. Group C rats that received 15mg/kg of diesel showed increase gut motility which is in line with Schmidt et al 1997. Increased intestinal motility is suggestive of diarrhea which may be due to some bacterial agents found in diesel (Delfino 1997) and it appears that toxicity depends on concentration and duration

of exposure (Odogwu 1997). Comparing the control group and experimental groups, the difference in motility was not significant. Histological studies in this research revealed intact intestinal ileum architecture of control rats. However, the group that received 10mg/kg showed minimal distortion of the mucosal layer and other layers. The 15mg/kg shows severe degeneration of layers of the mucosal layer with its adjoining sub mucosal and its contents.

CONCLUSION

In conclusion, oral ingestion of diesel contaminated water may be hazardous even at low concentration.

REFERENCES

1. Ackermann-Liebrich. Lungs function and long term exposure to air pollutant and lungs disease in adults *Am Respir Crit Care Med* **155**(1): 122-129 (1997).
2. Brenniman GR, Aver MR, Hartung R, Rosenbeg SH Effect of outboard motor exhaust emission on gold fish (*carasscus auratus*) **2**(6): 1267-1285 (1979).
3. Brunkreef B air pollution from truck traveller and lungs function in children living near motor way *Epidemiology* (**8**): 298-03 (1997).
4. Delfino Rj Murphyand Moulton AM effect of pollution on emergency room visits for respiratory illness *Amj Respirb Crit Care Med*, 568-526 (1997).
5. Odogwu E C.Oil spillage and control “Measures Shell experience”. Paper presented at the workshop on “Development of petroleum and petro-chemical industries in Nigeria, University of Ibadan: 25-29 (1997).
6. Naser Montazeri, Z. Barami and Safar-Ali-Dorrieh. *Orient J. Chem.* **27**(4): 1317-1324 (2011).
7. Mauderly J C diesel Exhaust in Lippman. Environmental toxicants human exposures and health effect (1992) .
8. McClellan R.O. Health effect of exposure to diesel exhaust particles. *Annu Rev Pharmacol Toxicol*, **27**: 279-300 (1987).
9. Material Safety Data Sheet. Diesel Fuel (All Types) MSDS No. 9909. 1-7 (2006).