

Present Status, Future Road Map and Diagnosis of Zoonotic Mycotic Diseases

RAYAZ AHMED, F.A.DAR and BILAL GOJRI

Sri Venkateswara Veterinary university Tirupati - 517 502, India.

DOI: <http://dx.doi.org/10.13005/bpj/443>

(Received: August 10, 2013; Accepted: September 20, 2013)

INTRODUCTION

Mycotic diseases not only affect the animal health but also make the country's live stock Industry uneconomic, as they often lead to mastitis, decreased milk yield, abortions, sterility, deterioration of hide quality and above all diminished general performance.

Due to prolonged and indiscriminate use of antibiotics and steroids in Intra-mammary therapy for mastitis, as well as prevalence of fungal organisms on dairy farms, the incidence of Mycotic Mastitis is on the rise and the most frequently isolated fungi from Mycotic Mastitis in dairy animals in India, are *Cryptococcus neoformans* and *Candida albicans*.

Systemic Mycotic diseases often pose a difficult diagnostic challenge for clinicians due to lack of any pathognomonic clinical syndrome and characteristic Radiographic feature. In India, the problem is further confounded by the preponderance of tuberculosis and paucity of diagnostic mycological laboratories. Consequently, patients suffering from systemic mycoses may be mistaken as Tuberculosis or other bacterial diseases.

Among the emerging mycotic diseases in animals, documented in India, are Aspergillosis, Zygomycosis, Cryptococcosis and Candidiasis. Most of the reports of these diseases are based on the Isolation of fungi by microbiologists or Mycologists. In many cases, these fungi may be just contaminants, without being associated with the Pathological Lesion and the wrong diagnosis can be made.

For diagnosis of mycotic diseases, demonstration of fungal material by special stains in the pathological lesion is a must. The correct and early diagnosis is a key factor in the treatment of mycotic diseases.

Diagnosis of mycotic diseases

- a By the isolation of fungus in the culture.
- b By histopathology using special stains like grocott's- methenamine silver, PAS & GRIDLEY Staining.
- c By Immunohistochemistry with monoclonal antibodies, using indirect FAT and immunoperoxidase test.
- d Recently sero-diagnosis to detect igG and igM have been used using DOT-ELISA
- e Cutaneous hypersensitivity test has also been attempted by few workers.
- f Genetic diagnosis including the use of PCR is still under Investigation, but this method suffers from low specificity and sensitivity.
- g Diagnosis by X-rays, CAT-SCANS, ultrasound and MRI do not differentiate mycotic lesions from tuberculosis and cancerous growths.

Accordingly, in most cases of mycotic infections, microscopic examination of biopsy or FNAC is the most reliable method of diagnosis even today. But for this purpose, the pathologist should have enough training because the morphology of the fungus and histopathology of the lesion varies according to the route of infection and at different stages of the disease, right from the onset of infection up to its termination.

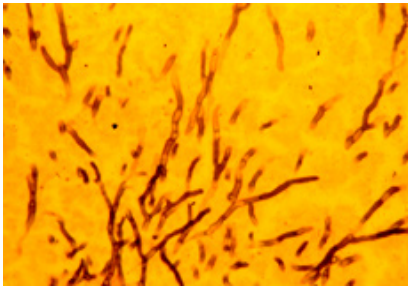


Fig. 1: Septate & dichotomously branching *Aspergillus* hyphae (GMS)

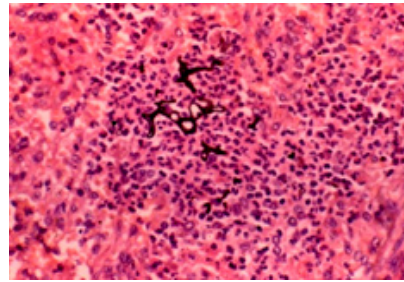


Fig. 2: Early Zygomycotic pyogranuloma in lung (HE + GMS)

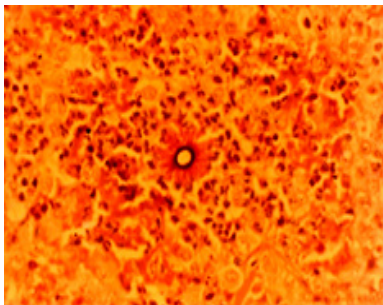


Fig. 3: Cross section of fungal hyphae surrounded by splendor hoespli bodies

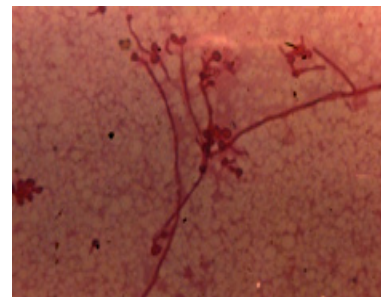


Fig. 4: Hyphae, pseudohyphae and budding yeasts of *Candida albicans* in the mastitic milk smear (PAS)

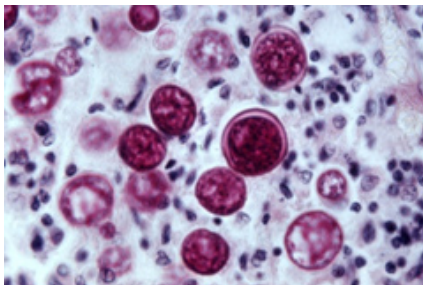


Fig. 5: Yeast cells in dog lung tissue. PAS, 400X

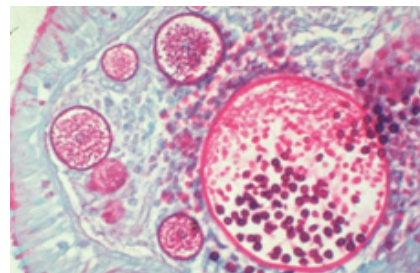


Fig. 6: Sporangia showing different stages of sporangiospore development in the large sporangium, nasal polyp, PAS stain

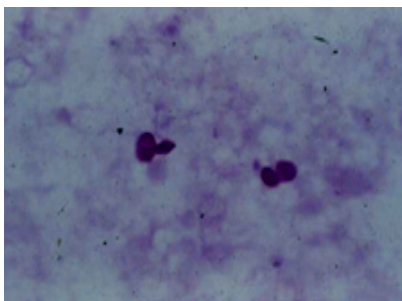


Fig 7: Budding cryptococcus yeasts in the mastitic milk smear (PAS)

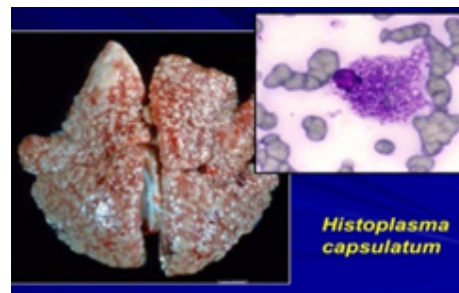


Fig 8: *Histoplasma capsulatum*

Therefore, for the benefit of young fresh myco-pathologists and post graduate students, I will now show some histopathological slides from some of the mycotic diseases.

CONCLUSIONS

Respiratory and systemic mycoses are globally emerging as a problem of increasing importance in infectious diseases. This is attributed to the growing population of immunocompromised patients due to epidemic outbreak of AIDS or to other factors such as use of immunosuppressive drugs in recipients of organ transplantation.

Since respiratory and systemic mycoses have no pathognomonic clinical or radiologic

syndrome and mycological diagnostic facilities are restricted to only some of the major metropolitan centres, these diseases may be frequently confused with tuberculosis or other diseases of obscure etiology in India and other developing countries.

Greater awareness and a high index of clinical suspicion are important pre-requisites for their diagnosis. Also, active collaboration of clinicians, pathologists, mycologists and microbiologists is advocated for their expeditious diagnosis and successful management, and in order to cope with the challenge of systemic mycoses, the health authorities of the developing countries are called upon to urgently take necessary measures for establishing a network of diagnostic medical and veterinary mycology laboratories.

REFERENCES

1. Govindarajan, D. and Chauhan, R.S., Fungal diseases of cattle and buffaloes. *Pashudhan*. **16** : 1 – 8 (2001).
2. Gupta, P.P. and Mandal, P.C., Pathological alterations in goats intravenously infected with *Aspergillus fumigates*. *Indian J. Anim. Sci.* **69**: 381 – 384 (1999).
3. Gupta, P.P., Singh, G., Sodhi, S. and Sood, N., Sequential clinical, haematological, biochemical, immunopathological and histopathological alterations in buffalo-calves (*Bubalus bubalis*) intravenously infected with *absidia corymbifera*. *Trop. Anim. Hlth. Prod.* **31**: 143 – 160 (1999).
4. Gupta, P.P., Singh, G. and Sodhi, S., Haematological, biochemical and immunopathological studies in buffalo-calves intravenously infected with *Absidia corymbifera*. *Indian J. Comp. Microbiol. Immunol. Inf. Dis.* **30**: 58-61 (1999).
5. Kindo, A.J., PCR in diagnosis of fungal infections. 8th National Conf. SIHAM, 4 – 6 March, 2010 at A.I.I.M.S., New Delhi (2010).
6. Kumar, R. and Thakur, S.D., Fungal diseases of large animals. *Livestock – International*. **7**: 8 – 10 (2003).
7. Mandal, P.C. and Gupta, P.P., Sequential pathological studies in goats infected intratracheally with *Aspergillus fumigates*. *Mycopathologia*. **121**: 77-81 (1993).
8. Mandal, P.C. and Gupta, P.P., Experimental aspergillosis in goats : Clinical, haematological and mycological studies. *J. Vet. Med. B.* **40**: 283 – 286 (1993).
9. Mandal, P.C. and Gupta, P.P., Sequential pathological studies in the udder of goats intramammarily infected with *Aspergillus fumigatus*. *Mycopathologia*. **126**: 9-14 (1994).
10. Randhawa, H.S., Is blastomycosis endemic in India. 8th National Conf. SIHAM, 4 – 6 March, 2010, A.I.I.M.S., New Delhi (2010).
11. Randhawa, H.S., Histoplasmosis: An overview of its prevalence and diagnosis. 8th National Conf. SIHAM, 4 – 6 March, 2010, A.I.I.M.S., New Delhi (2010).
12. Sestero, C.M. and Scalarone, G.M. Detection of IgG and IgM in sera from canines with blastomycosis. *Mycopathologia*. **162**: 33-37 (2006).
13. Shastri, J., Rhinosporidiosis – a case report. 8th National Conf. SIHAM, 4 – 6 March, 2010, AIIMS, New Delhi (2010).
14. Singh, G., Gupta, P.P., Sood, N., Banga, H.S. and Jand, S.K., Sequential pathological studies in Asian water buffaloes infected intratracheally with *Absidia corymbifera*. *Rev.*

- Iberoam. Micol.* **15**: 146-150 (1998).
15. Singh, G., Gupta, P.P., Sood, N. and Banga, H.S., Pathological alterations in buffalo calves intravenously infected with *Absidia corymbifera*. *Indian J. Anim. Sci.* **68**: 1023 – 1027 (1998).
 16. Singh, M., Gupta, P.P., Rana, J.S. and Jand, S.K., Clinico-pathological studies on experimental cryptococcal mastitis in goats. *Mycopathologia.* **126**: 147 – 155 (1994).
 17. Singh, M., Roy, K.S., Rana, J.S., Gupta, P.P. and Sood, N., Experimental cryptococcal mastitis in goats: histochemical studies. *Indian J. Anim. Sci.* **65**: 742 – 745 (1995).
 18. Singh, M., Gupta, P.P., Rana, J.S., Sodhi, S. and Sood, N., Biochemical changes in milk in cryptococcal mastitis of experimental goats. *Indian J. Dairy Sci.* **47**: 1043 – 1049 (1994).
 19. Singh, P., Sood, N., Gupta, P.P., Jand, S.K. and Banga, H.S., Experimental candidal mastitis in goats: clinical, haematological, biochemical and sequential pathological studies. *Mycopathologia.* **140**: 89-97 (1998).
 20. Sondhi, J., Gupta, P.P., Effect of immunosuppression on the clinicopathological changes in experimental zygomycosis in rabbits. *Vet. Res. Commun.* **24**: 213 – 227 (2000).
 21. Sondhi, J., Gupta, P.P. and Sood, N., Effect of immunosuppression on the pathogenesis of respiratory zygomycosis in rabbits intranasally infected with *Absidia corymbifera*. *Rev. Iberoam. Micol.* **16**: 107-110 (1999).
 22. Sondhi, J., Gupta, P.P., Sood, N. and Singh, J., Pathological and histochemical studies in experimental zygomycosis in rabbits. *Indian J. Anim. Sci.* **69**: 694-696 (1999).
 23. Sondhi, J., Gupta, P.P. and Sood, N., Experimental zygomycosis in rabbits: Clinicopathological studies. *Mycopathologia.* **144**: 29-37 (1999).
 24. Sood, N., Rana, J.S., Misri, J., Banga, H.S., Jand, S.K. and Gupta, P.P., Experimental cryptococcosis in buffalo calves. *Buffalo J.* **12**: 139-145 (1996).
 25. Vidhya, P.S., Nagarajan, B., Manohar, B.M., Srinivasan, S.R., *Histoplasma colitis* in a dog a case report. *Tamilnadu J. Vet. Anim. Sci.* **2**: 151-153 (2006).