

## Recurrent Aphthous Stomatitis - A Review

S. LEENA SANKARI<sup>1</sup>, K.M.K. MASTHAN<sup>2</sup>, N.ARAVINDHA BABU<sup>3</sup> and C. PRIYADHARSINI<sup>4</sup>

<sup>1-4</sup>Department of Oral Pathology and Microbiology,  
Sree Balaji Dental College & Hospital, Bharath University, Chennai, India.  
Corresponding author E-mail: priyadharsinichandrasekar@gmail.com

(Received: April 25, 2013; Accepted: May 28, 2013)

### ABSTRACT

Oral ulcers are diverse in number. Recurrent aphthous ulceration is the most common form of painful ulcerations in oral cavity. The diagnosis is well defined but the etiology and pathogenesis remains unclear. It is common condition affecting 20% of general population. This review article provides the exact etiology, diagnosis, criteria and treatment of RAS.

**Key words:** Oral ulcers, Recurrent aphthous stomatitis, Corticosteroids

### INTRODUCTION

Oral ulcers are diverse with a wide variety causes. Among the oral ulcers, Recurrent aphthous stomatitis (RAS) is the most common form of ulceration. It is a disease characterized by episodic appearance of oral ulcers in which etiology and pathophysiology remains unclear. The word aphthous was originated with Hippocrates in 460-370BC in reference to disorders of mouth (Terri.S.I. *et al.* 2002). It is a widespread disorder affecting at least 5% to 66% of examined adult patient groups. Frequently the affected groups find difficulty in eating and speaking (Srinivas Rao *et al.*, 2010). The cause is multitude in number with many precipitating factors. There are three clinical presentations of RAS they are major, minor and herpetiform. Minor RAS affects for about 80% and Major RAS for about 10% of the RAS patients. Herpetiform ulcers are seen constitute 10% of the all RAS patients

#### Etiology

The exact etiology of RAS is unidentified. On a survey, 10-20% of patients with RAS had deficiencies of iron, folic acid or vitamin B12. 2-3% of patients were related to celiac disease and haematinic deficiency. Numerous investigations and investigators, studies have been unsuccessful to find the exact etiology and pathophysiology of RAS.

They are various systemic diseases which are associated with RAS such as cyclic neutropenia, agranulocytosis, Behcet's syndrome is related with RAS, which has been documented. RAS is also associated with other syndrome such as SWEET's syndrome, MAGIC syndrome and PFPA syndrome. Some predictable factors which are accountable for recurrent aphthous stomatitis are heredity, immune dysregulation, certain foods, stress, hormonal disturbances, local trauma, infections, drugs, smoking habits, and poor oral hygiene. (Serap Koybasi *et al* 2006)

#### Role of micro organism in aphthous ulcer *Helicobacter pylori*

They are many micro organism studied in the pathogenesis of RAS. *Helicobacter Pylori* has been recently attracted the concentration of many investigators. In 1983, the germ was isolated for the first time from a human gastric biopsy specimen. The bacterium was isolated from dental plaque in 1989 (Mansour *et al* 2005). *H.pylori* is a gram negative bacterium commonly found in gastric mucosa. It has been found in saliva, sub-gingival region and also detected in dental plaque. Many facts have suggested that oral cavity is a reservoir of the organism. Oral cavity is a possible route of transmission to other sites (Anak Iamaroon *et al*, 2003). So the secondary source of infection was considered as oral cavity.

### Oral Streptococci

Streptococci are one of the microbial agents which are measured in the pathogenesis of RAS. It is recommended that L form of  $\alpha$ - hemolytic streptococci were strongly implicated in RAS. The causative organism of the disease is *Streptococcus sanguis*. Some studies have recommended that there is cross reactivity found between streptococcal 65-kDa heat shock protein and 60-k-Da human mitochondrial hsp. Accordingly, RAS could be a T-cell-mediated response to antigens of *S. sanguis* to facilitate cross-react with the mitochondrial hsp and provoke oral mucosal damage. *Streptococcus mitis* was another causative agent of RAS which was later identified. (Lehner T *et al*, 1991).

### Virus

There are been many suggestive factors for virus as an etiologic agent in RAS. But still there exist questionable evidence towards viral etiology. Epstein-Barr virus has been studied in patients with RAS. Thus virus was associated with epithelial cells of pre Ulcerative RAS (Sun A *et al*, 1998 )

### Immunologic factors

Much of the research, for the past 30 years focused on the cause of RAS on detecting the abnormality in the immunologic response. Deposition of immune complexes within the oral epithelium induces multiple immune reactions to cause damage. There is a strong association between abnormal proportions of CD4+ and CD8+ cells and RAS severity, elevated levels of interferon gamma, interleukin 2 and tumor necrosing factor  $\alpha$ , and alteration of CD4+:CD8+ ratio in RAS lesions.

Biopsy tissues of RAS staining with immune histochemistry techniques revealed numerous inflammatory cells with unpredictable ratio of CD4+:CD8+: T lymphocytes. During pre-ulcerative and healing stages CD4+ cells were numerous, but during ulcerative state CD8+ cells tend to be numerous (Mahesh Chavan *et al* 2012)

### Nutritional deficiency

Loads of data advocate that nutritional deficiency as a cause for RAS. Patients with low serum levels of iron, folate, zinc, or vitamins B<sub>1</sub>, B<sub>2</sub>, B<sub>6</sub>, and B<sub>12</sub> has been allied with a small subset of

5% to 10% of RAS patients (Nolan A *et al* 1991). Malabsorption syndrome and gluten sensitivity are associated with RAS. Calcium and vitamin C deficiency has been proposed in patients with RAS recently (Ogura M *et al* , 2001)

### Precipitating factors

Many factors have been proposed. They are

#### Local factors

Trauma is one of the major contributing agents for RAS. RAS is predisposed by trauma. It is predisposed by inducing edema, cellular inflammation. Generally not all trauma lead to RAS,. But denture wearers who are usually three times more vulnerable to ulceration (Stone OJ *et al.*, 1991)<sup>28</sup>. Compositions of saliva also play an essential role in RAS. Modification in salivary composition such as changes in Ph, affect the properties of saliva. Tumour necrosis factor- $\alpha$ , salivary nitric oxide are other salivary components that are positively associated with RAS (McCartan *et al* 1996)

Stress is one of another contributing factor for RAS. It has been estimated that stress may induce trauma to soft tissue with many functional habits such as lip biting, thumb sucking. This trauma may prompt to ulceration (Preeti.L *et al* 2011)

#### Allergic factors

Allergy has been assumed as one of the cause for RAS. RAS is associated with several kinds of food stuffs. Foods stuffs such as chocolate, cheese and tomatoes can precipitate the attack of RAS are recognized in some patients (Wardhana, E.A. *et al.*, 2010)

#### Drugs

Many drugs such as, captopril, angiotension converting enzyme inhibitor, , NSAIDS such as diclofenac sodium, gold salts, propionic acid have been projected as causative agents for RAS (Zain R.B. *et al* 1999)

#### Endocrine conditions

For many years, it was recommended that a affiliation exist between development of aphthous ulcer and occurrence of menstrual period. Cyclic RAS is observed in the luteal phase of the menstrual cycle for several women.

## **Systemic diseases with recurrent aphthous stomatitis**

### **Behcet's syndrome**

Behcet's disease is well thought-out as a chronic inflammatory disease of unknown etiology. But now considered as a systemic vasculitis of uncertain aetiology. (Gabriel Riera Matute *et al.*, 2011)

This syndrome is characterized by recurrent oral (aphthous) ulcers, genital ulcers, and skin lesions. Experimental observations suggest that aphthous ulcers are seen in patients with Behcet's syndrome. They emerge to be allied with increased tissue oedema and appear to have an extremely erythematous border. The aphthae in Behcet's disease habitually occur in the soft palate and oropharynx. Ulcers have also been seen on the hard palate, which is the most abnormal site for RAS in patients without Behcet's disease (Kovacova E, *et al.*, 2005)

### **PFAPA syndrome**

The PFAPA, or Marshall's, syndrome was formerly reported in 1989. Several patients had a history of 3 to 6 days of fever, along with pharyngitis and aphthous stomatitis. In a percentage of patients acute episodes of fever are seen along with recurrent aphthous stomatitis. But children have uneven symptoms in free intervals. The oral lesions are described generally as small, shallow, round ulcerations. These ulcerations are present in the buccal mucosa or on the tongue surface which is bounded by erythema. The oral stomatitis in PFAPA syndrome prevalence was in the beginning reported to be as high as 70%. Recent follow-up, shows a predominance to less than 30%. (Andres Pinto, *et al* 2006)<sup>20</sup>

### **Cyclic neutropenia**

It is a uncommon hematological disorder. Cyclic neutropenia is characterized by recurrent fevers, mouth ulcers, and infections attributable to habitually recurring severe neutropenia. Generally, the child often less than 1 year of age, who presents with recurrent fever, pharyngitis, mouth ulcers, and lymphadenopathy, recurrent cellulitis is assumed for diagnosis. Classically, the mouth ulcers are very deep which is very painful and which often last a week or more (David C. Dale *et al.*, 2002). Cyclic

neutropenia (CN) is habitually characterized by a transient decrease in the neutrophil count, with a periodicity of around 21 days (range, 14 to 36 days) (Marcio A *et al* 2000).

### **Clinical presentation**

Recurrent aphthous stomatitis have been classified in to three forms they are:

#### **Minor Recurrent Aphthous Stomatitis**

It is the familiar presentation affecting about 80% of patients. The ulcers are oval or round, recurrent, clearly defined and usually <5mm in diameter. These ulcers are very small and very painful. It is also Miculiz'sapthae. It constitutes for about 80% of RAS. It is generally seen in the nonkeratinized mucosal surface like labial mucosa. Minor ulcers often heal within 10 to 14 days without scarring.

#### **Major RAS**

It is also known periadenitis mucosa necrotica recurrens or Sutton disease. It is rare, form of RAS. Most frequently seen in lips, soft palate and fauces. These ulcers are larger usually greater than 5mm . The ulcer persists for six weeks in addition it frequently scars and often heals.

#### **Herpetiform Ulceration**

Herpetiform ulceration is least common and third variety RAS. These ulcers present as multiple small clusters of pinpoint lesion. These ulcers coalesce to form large irregular ulcers. Many ulcers may be present. Each measuring 2 to 3mm in diameter in size. It generally have a predisposition for women. These ulcers last for 7 to 10 days (Ship J A, *et al.*, 1996).

#### **HIV Associated Aphthous ulcers**

Large aphthous like ulceration are seen associated with HIV positive patients with a prevalence of approximately 2-3%. The large solitary or multiple, chronic, deep, painful ulcerations and they often last much longer and are less responsive to therapy

#### **Pathogenesis**

The pathogenesis remains unknown. It has strong hereditary component and appears to be related to an immune reaction against the oral

**Characteristic of different forms of recurrent aphthous stomatitis (Stephen R. Porter *et al.*, 2000)**

	Minor	Major	Herpetiform	Hiv-associated <sup>90</sup>
Shape	Oval	Oval or crateriform	Oval	
Number	1-5	>1-10	10-100	1-5
Size	<0.5	>0.5	<0.5	>1cm
Location	Non keratinized Mucosa	Non keratinized Mucosa	At any site in oral cavity	Non keratinized Mucosa

mucosa. The lesions of RAS are not caused by a single factor. But it occurs in an environment that is permissive for development of lesions. (Kilic SS. *et al.*, 2004).

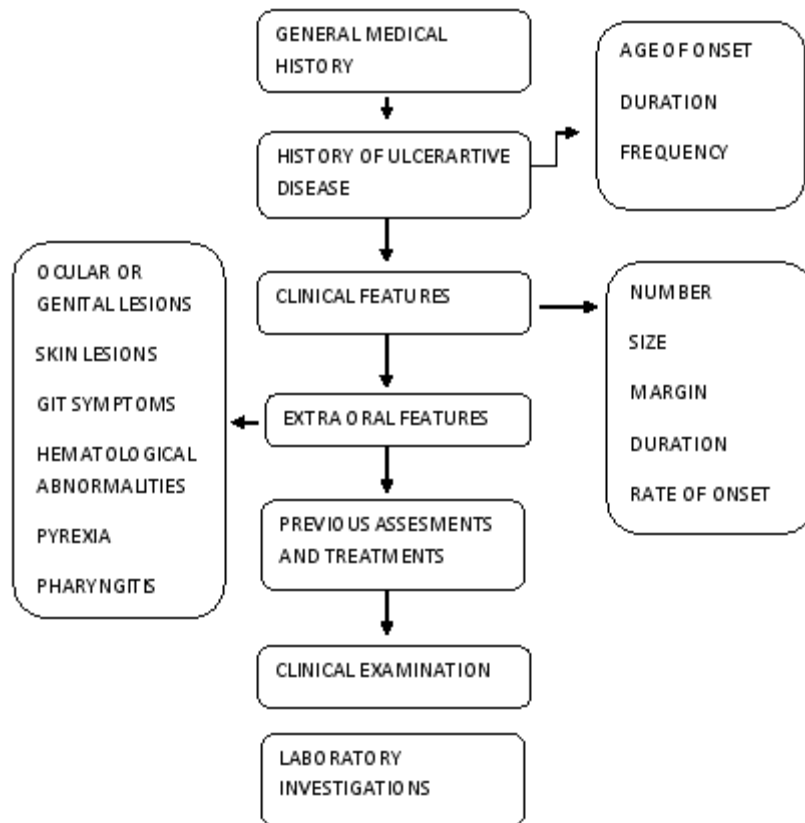
some immunopathological features that involve T-cell mediated immunity. It is suggested that RAS is a delayed type hypersensitivity or it is a cell-mediated response to an antigen stimulus residing within the epithelium. (E. A. Field & R. B. Allan *et al.*, 2003)

**Immunological Mechanism**

Recurrent aphthous ulcerations involve immunopathological mechanisms that account for loss of adhesion between contiguous keratinocytes or to structure within the basal lamina. They have

**Diagnosis**

There is no particular diagnostic test. A complete and exact patient history is significant to the diagnostic process. Systemic diseases are existing



**Scheme 1: A Sequence for the diagnostic process (V Vucicevic Boras *et al.*, 2007)**

with recurrent aphthous stomatitis. The diagnostic is based on clinical history and histopathology. Infrequently uses of cultures are desired to make a definitive diagnosis. Histopathology of RAS is not a diagnostic. The diagnosis is reliant upon clinical history ( C. Scully<sup>1</sup> *et al.*, 2005)

#### Differential diagnosis

Several medical disorders are associated which may resemble RAS.

They are bechet's syndrome, MAGIC syndrome, Sweet's syndrome, PFAPA syndrome, cyclic neutropenia, HIV, Crohn's disease.( Andres Pinto, *et al.*, 2006)

#### Topical therapy

Category	Effects
Anti microbial therapy &Antiinflammatory	
Chlohexidene	Mildly inhibits inflammation
Triclosan	Anti-inflammatory,
Diclofinac	Antiseptic analgesic effect
Dexpanthenol	
Topical sucralfate	Soothing effect on lesion by adhering to mucous membrane tissue
Topical steroids	Combination therapy with a topical anesthetic is widely accepted as the optimal treatment regimen
Triamcinolone acetonoid	
Prednisocone	
Newer findings	1: To apply of 5-aminosalicylic acid 5% cream 2: A topical prostaglandin E2 gel 3: Raw egg white may partially soften oral pain

#### Systemic therapy (SB Woo *et al.*, 1996)

Colchicine	To reduce the number and duration of lesions
Pentoxifylline	Effective against orogenital aphthae
Corticosteroids	Rescue treatment in patients with acute exacerbation and in those who inadequately responded to therapy with colchicine and pentoxifylline.
Dapsone	Oral and genital aphthae
Thalidomide	A dose-dependent effect against orogenital ulcerations emerges within 7-10 weeks following treatment Antimetabolites
Azathioprine	Reduce the frequency and extent of severe orogenital
Methotrexate	aphthosis. Effective in severe orogenital aphthosis.
Cyclosporine A	Effective in about 50% of patients
Interferon-alpha	Is shown to be effective within 1-4 months

#### Adverse effects of drugs during RAS therapy (Crispian scully, *et al.*, 2003)

Drugs	Adverse effects
Colchicine	It causes very painful gastrointestinal symptoms, fertility in male and diarrhea.
Dapsone	It causes Mathemoglobinemia
Levamisole	It effects decrease in white blood cells
Pentaxifylline	It causes nausea
Thalidomide	It causes polyneuropathy, tetrogenicity

**Treatment**

The treatment depends on frequency, size and number of ulcers. The treatment still remains non specific.( A. Altenburg, *et al.*, 2008)

The goals of the therapy include the functional impairment by suppressing inflammatory response, management of pain, reducing the frequency of recurrence and avoiding the onset of new aphthae. (Khoo.sp *et al.*,1999)

**Physical therapy**

1. Surgical removal

2. Laser ablation
3. Dietary and gential measures
4. Cauterization

**CONCLUSION**

The RAS is the common form of painful ulcerations of oral cavity. Although it is the common form of presentation the etiology and pathogenesis remains unclear. The diagnosis mainly depends on the clinical features and not on the histopathology report. Management of RAS only provides symptomatic relief by reducing pain.

**REFERENCES**

1. Terri.S.I. Tilliss, John Mc Dowell, "Differential Diagnosis: Is It Herpes or Aphthous?" **3**(1): 15 (2002).
2. Srinivas Rao Recurrent Aphthous Stomatitis: A Review *J Orolfac Sci*, **2**(3): (2010).
3. Serap Koybasi, Ali Haydar Parlak, Erdinc Serin, , Fahrettin Yilmaz, , Didem Serin, Recurrent aphthous stomatitis: investigation of possible etiologic factors *American Journal of Otolaryngology–Head and Neck Medicine and Surgery* **27**: 229– 232 (2006).
4. Mansour-Ghanaei F, Asmar M, Bagherzadeh AH, Ekbataninezhad S. Helicobacter pylori infection in oral lesions of patients with recurrent aphthous stomatitis 2005 **11**(12): CR576-9. Epub 2005 Nov 24.
5. Anak Iamaroon§, Siriporn Chaimano§, Sukanya Linpisarn†, Surawut Pongsirivet§ and Kannikar Phornphutkul Detection of *Helicobacter pylori* in recurrent aphthous ulceration by nested PCR *Journal of Oral Science*, **45**(2): 107-110 (2003).
6. Lehner T, Lavery E, Smith R, van der Zee R, Mizushima Y, Shinnick T. Association between the 65-kilodalton heat shock protein, Streptococcus sanguis, and the corresponding antibodies in Behget's syndrome. *Infect Immunol* **59**: 1434–41 (1991).
7. Sun A, Chang JG, Chu CT, Liu BY, Yuan JH, Chiang CP. Preliminary evidence for an association of Epstein-Barr virus with pre-ulcerative oral lesions in patients with recurrent aphthous ulcers or Behcet's disease. *J Oral Pathol Med* **27**: 168–75 (1998).
8. Mahesh Chavan<sup>1</sup>, Hansa Jain<sup>2</sup>, Nikhil Diwan<sup>1</sup>, Shivaji Khedkar<sup>3</sup>, Anagha Shete<sup>1</sup>, Sachin Durkar Recurrent aphthous stomatitis: . review **13** (2012)
9. Nolan A, McIntosh WB, Allam BF, Lamey PJ. Recurrent aphthous ulceration: vitamin B1, B2 and B6 status and response to replacement therapy. *J Oral Pathol Med* **20**: 389–91 (1991).
10. Stone OJ. Aphthous stomatitis (canker sores): a consequence of high oral submucosal viscosity (the role of extracellular matrix and the possible role of lectins). *Med Hypotheses* **36**: 341-4 (1991).
11. McCartan BE, Lamey PJ, Wallace AM. Salivary cortisol and anxiety in recurrent aphthous stomatitis. *J Oral Pathol Med* **25**: 357-9 (1996).
12. Preeti.L, Magesh.K.T, Rajkumar.K. Ragavendhar karthik. Recurrent aphthous stomatitis: a review **15**(3): (2011)
13. Wardhana, E.A. Datau Recurrent Aphthous Stomatitis Caused by Food Allergy **42**(4): (2010).
14. Zain R.B. Classification, epidemiology and aetiology of oral recurrent aphthous ulceration stomatitis, *Annal Dent Univ Malaya* **6**: 34-37 (1999).
15. Gabriel Riera Matute,a, Elena Riera Alonso Recurrent Aphthous Stomatitis in

- Rheumatology *Reumatol Clin.* **7(5)**:323–328 (2011).
16. Kovacova E, Salmas,J, Bedeova J, Duris I, Bechet's syndrome *Bratisl Lek Listy* **106(12)**: 386-389 (2005).
  17. David C. Dale, Audrey Anna Bolyard, and Andrew Aprikyan Cyclic Neutropenia Seminars in Hematology, **39(2)** pp 89-94 (2002).
  18. A. da Fonseca, DDS, MS, Fernanda Fontes, DDS, MS Early tooth loss due to cyclic neutropenia: long-term follow-up of one patient *Special Care In Dentistry*, **20(5)**: (2000).
  20. Ship JA. Recurrent aphthous stomatitis. An update. *Oral Surg Oral Med Oral Pathol Oral Radiol Endod.* **81(2)**: 141 (1996).
  21. Stephen R. Porter, Anne Hegarty, Fotini kaliakatsou, Tim a.Hodgson, Rcs mrcp (uk), Crispian Scully, Recurrent Aphthous Stomatitis *Clinics in Dermatology Y* **18**: 569-578 (2000)
  22. Kilic SS. Recurrent aphthous stomatitis. *Recent Advances in Pediatrics*, Jaypee Brothers Medical Publishers, New Delhi, ISBN 81-8061-297-X, pp 63-75 (2004).
  23. E.A. Field & R.B. Allan Review article: oral ulceration – aetiopathogenesis, clinical diagnosis and management in the gastrointestinal clinic *Aliment Pharmacol Ther* **18**: 949-962 (2003).
  24. C. Scully<sup>1</sup> and D. H. Felix<sup>2</sup> Aphthous and other common ulcers *British dental journal* **199(5)**: 10 (2005).
  25. V Vucicevic Boras,\* NW Savage Recurrent aphthous ulcerative disease: presentation and Management *Australian Dental Journal* **52(1)**: 10-15 (2007).
  26. Andres Pinto, Rochelle G. Lindemeyer, and Thomas P. Sollecito Philadelphia, Pennsylvania The PFAPA syndrome in oral medicine: Differential diagnosis and treatment *Oral Surg Oral Med Oral Pathol Oral Radiol Endod* **102**: 35-9 (2006).
  27. A. Altenburg, C. Zouboulis, Current Concepts in the Treatment of Recurrent Aphthous Stomatitis **13(7)**: (2008).
  28. Khoo.sp Management of oral recurrent aphthous stomatitis (oras) *annals of dentist/ y, university of malaya*, **6** (1999).
  29. SB Woo and ST Sonis Recurrent aphthous ulcers: a review of diagnosis and treatment *J Am Dent Assoc* **127**: 1202-1213 (1996)
  30. Crispian scully, Francina Lozada nur, The diagnosis and management of Recurrent aphthous stomatitis, *JADA* 134 (2003).