

Pathological Changes of Gentamicin in Liver Tissue and Antioxidant Property of Cinnamon Extract on Wistar Rats

MAHMOOD NAJAFIAN^{1*}, HALEH MOKABER², MOHAMMAD POURAHMADI³,
MOHSEN FARZAM⁴ and HOSSEIN KARGAR JAHROMI³

¹Department of Biology, Jahrom Branch, Islamic Azad University, Jahrom, Iran.

²Department of Developmental Biology, Science and Research Branch, Islamic Azad University, Fars, Iran.

³Department of Anatomy, Jahrom University of Medical Science, Jahrom, Iran.

⁴Department of Veterinary, Kazeroon Branch, Islamic Azad University, Kazeroon, Iran.

*Corresponding author E-mail: d.najafian@jia.ac.ir

<http://dx.doi.org/10.13005/bpj/496>

(Received: May 25, 2014; Accepted: June 26, 2014)

ABSTRACT

The most vulnerable tissue against damages and side effects of medications is the liver tissue. Among the medications, most frequently used ones are antibiotics with among which toxicity with aminoglycosides, especially gentamicin has special importance. Studies have shown that gentamicin exerts its hepatotoxicity property through creating free radicals. Cinnamon has antioxidant properties. In This research the antioxidant properties of cinnamon in reducing hepatotoxicity property caused by gentamicin is studied. In this study, effect of gentamicin as 100mg/kg-BW (G), cinnamon extract as 200mg/kg-BW (C200) and gentamicin with the dosages of 50, 100 and 200mg/kg-BW of cinnamon extract (GC50, GC100 and GC200) on rats was studied. The results of research show severe destroy of tissue in the liver in G. Activity of the pyruvate transaminase, oxaloacetate transaminase, and alkaline phosphatase in G were significantly increased ($P < 0.05$) compared to control group. In GC50, GC100 and GC200, roughly proportional to the dose of cinnamon extract, enzyme activity reduced compared to G ($P < 0.05$). The tissue results also indicate tissue damage caused by gentamicin and healing by antioxidant properties of Cinnamon in GC200. It may be concluded that cinnamon extract with its antioxidant properties reduces liver damage caused by gentamicin.

Key words: Hepatotoxicity, Gentamicin, Cinnamon, Rats.

INTRODUCTION

One of the most widely used class of drugs are antibiotics. These drugs prevent many problems caused by infections. However, antibiotics have side effects and can damage various body organs including liver, kidney, brain, blood, skin, eyes, mouth, etc. ¹. Aminoglycosides antibiotics, especially gentamicin are widely used to treat severe infections of Gram-negative bacteria². Clinical use of gentamicin despite clinical benefits has been limited

due to its side effects. The main side effects include liver damage that is one of the major factors of liver inefficiency in a significant number of people taking this medication. Therefore taking these medications face limitations due to the fact that one of the major side effects of Gentamicin is creating hepatotoxicity³⁻⁵. Increased production of Reactive Oxygen Species (ROS), which can be seen after the use of gentamicin in cells, is effective in inducing toxic impacts of this drug on the structure and function of tissues⁶⁻⁸.

Some studies have reported that oxidative stress has role in gentamicin-induced nephrotoxicity⁹. Gentamicin enhanced the production of superoxide anion, hydrogen peroxide and hydroxyl radicals by mitochondria¹⁰. Free radicals cause Peroxidation of phospholipids membrane, DNA strand breakage, protein denaturation. Most significant biological damage of active metabolites is their reaction with unsaturated lipid and so their peroxidation. This effect induces changes in membrane fluidity, thus the membrane gets permeable even to molecules as large as enzymes¹¹. Cinnamon is a plant with the scientific name *Cinnamomum zeylanicum* (C. Verum) and the generic name is Cinnamon. This evergreen tree belongs to Lauraceae family is native to Sri Lanka and southeast India. Cinnamon well as being used as flavor in foods and pastries, it has medicinal and therapeutic uses. This plant is one of the oldest medicinal plants that has been used as an important medication in traditional medicine. Different parts of this plant such as the skin has many health benefits, so that its use strengthens the heart, liver, stomach and intestines; improves kidney function and increase sexual power¹². Medicinal value of this plant is due to its volatile oil .the main componenets of this essence include Cinnamaldehyde, eugenol and Safrole that has activy similar to insulin and can be useful in the treatment of diabetes¹³. Also, these combinations are involved in decreasing triglycerides, cholesterol and LDL level¹⁴. Cinnamon has anti-bacterial and anti-fungal properties¹⁵. Cinnamon is used healing wounds and treating nausea and diarrhea¹⁵⁻¹⁶. This study investigated the antioxidant properties of cinnamon in reducing hepatotoxicity caused by gentamicin.

MATERIALS AND METHODS

The present study has been conducted experimentally and it is completely random. All ethical principles of working with experimental animals have been considered in this study. Thirty six Adult Male Wistar rats weighing 200 ± 10 g and 75 days of age were randomly divided into six groups and were housed in six cages. Length of experiment was 28 days during which the rats were kept in experiment conditions including 22 ± 2 ° C and cycle of 12 hours light and 12 hours dark. Rats ate standard food of rodent (pellete). The water was provided to them in glass bottles special for them.

They were allowed to eat food and water. Their Cage was disinfected with 70% alcohol three times a week. Different doses of Cinnamon extract were prepared in physiology serum and also ampoules of 100 mg in 2 mL of gentamicin were prepared. The Samples (serum physiology, cinnamon extract and gentamicin) in a volume of 0.4ml was injected with an insulin syringe intraperitoneally each day at 9 am. Thirty six Wistar rats were randomly divided into six groups and each group were subjected to the following treatments. S: Rats in this group received saline solution as solvent of cinnamon extract and gentamicin. C200: Rats in this group received cinnamon extract 200mg/kg B.W. G: Rats in this group received gentamicin 100mg/kg B.W.

GC50, GC100 and GC200: Rats in these groups received gentamicin 100mg/kg B.W with cinnamon extract 50, 100 and 200mg/kg B.W respectively.

The animals were anesthetized 28 days after being weighed and blood samples were taken from their heart; and their serums were collected. In Serum, activity of pyruvate transaminase (PT), oxaloacetate transaminase (OT), alkaline phosphatase (ALP) and also albumin and total protein was measured. Liver sample tissue was performed and after tissue processing, the tissue section slides were prepared and stained with eosin - hematoxylin and examined by light microscopy. Results were calculated as mean \pm SD and for comparison between treatments One-way analysis of variance (ANOVA) followed by Duncan's test for multiple comparisons between different groups were used. Significance level was considered as $P < 0.05$. For data analysis and statistical tests SPSS software, edited version 22 was used and diagrams were drawn using Excel software.

RESULTS

The results obtained from experiments are shown in diagrams. In these diagrams various groups were compared regarding parameters under study. The letters above columns in the diagrams is comparison of the significance of changes in various factors of groups. The means in columns that have at least one common letter have no significant differences with each other in $P < 0.05$.

Figure 1 shows activity of oxaloacetate transaminase in the various groups. OT activity in G showed a significant increase compared to S. In GC50, GC100 and GC200 that received different doses of cinnamon along with the gentamicin, enzyme activity was reduced and this reduction was significant in GC100 and GC200 compared G ($P < 0.05$).

As it is shown in Figure 2, PT activity in G showed a significant increase compared to S. In GC50, GC100 and GC200 that along with gentamicin, received various doses of cinnamon extract, enzyme activity was reduced and this reduction in GC200 was significant compared to G ($P < 0.05$).

As it is shown in Figure 3, ALP activity in G showed a significant increase compared to S. In GC50, GC100 and GC200 that along with gentamicin, received various doses of cinnamon

extract, enzyme activity was reduced, but the rate of decline was not significant compared to G ($P < 0.05$).

As it is shown in Figure 4, the amount of albumin in G showed a significant decrease compared to group S. In GC50, GC100 and GC200 that along with gentamicin received different doses of cinnamon extract, albumin increased and this rise was significant in GC100 and GC200 compared to G ($P < 0.05$).

Protein showed a significant decrease in G compared to S. In GC50, GC100 and GC200, that along with the gentamicin received different doses of cinnamon extract, the protein content increased and this increase was significant in GC200 compared to G ($P < 0.05$) (Figure 5).

The results of section tissue shows that S, which received saline solution hepatics retain their natural shape and no lymphocytic infiltration and

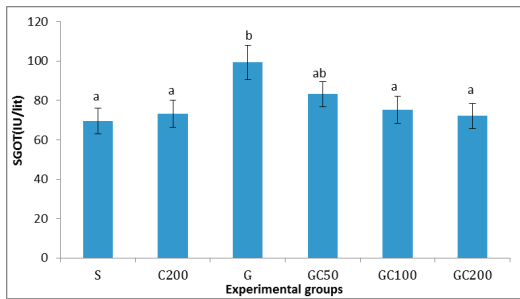


Fig. 1: Changes in activity of oxaloacetate transaminase enzyme with use of different doses of gentamicin and different doses of cinnamon extract

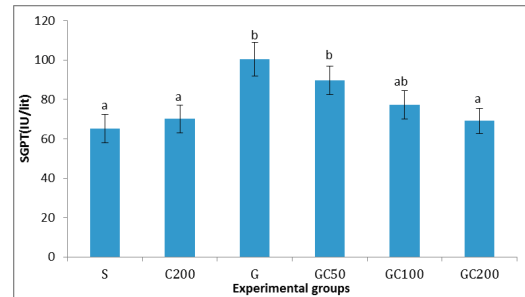


Fig. 2: Changes of pyruvate transaminase activity with use of gentamicin and different doses of and Cinnamon

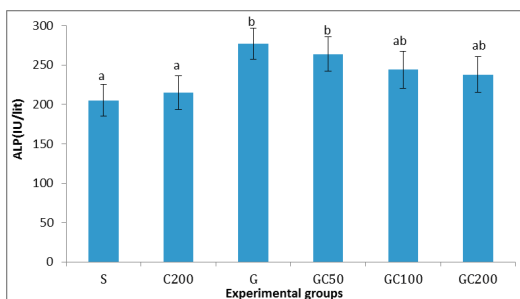


Fig. 3: Changes in activity of alkaline phosphatase enzyme with use of different doses of gentamicin and Cinnamon

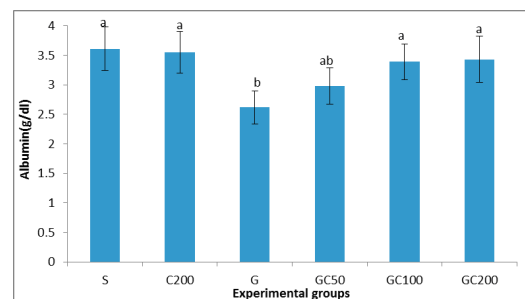


Fig. 4: Changes in albumin level with use of gentamicin and different doses of Cinnamon extract

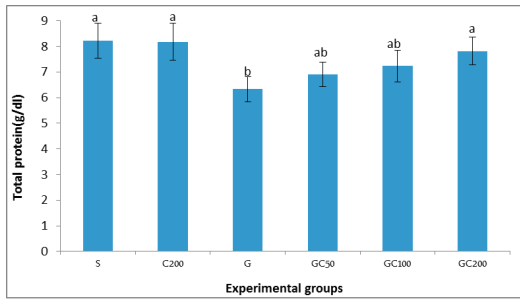


Fig. 5: Changes in protein level with use of gentamicin and of different doses Cinnamon

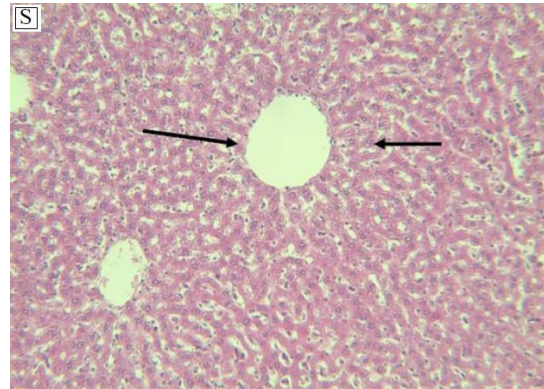


Fig. 6: Optical photomicrographic of liver tissue (H & E staining, magnification x 400)

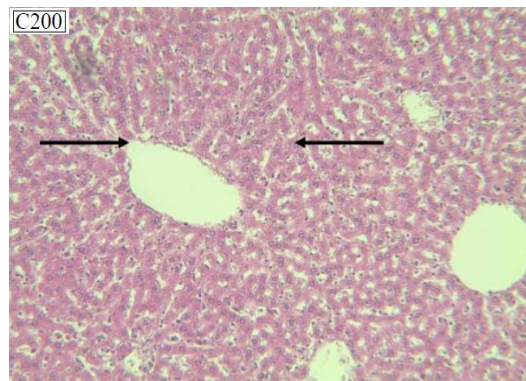
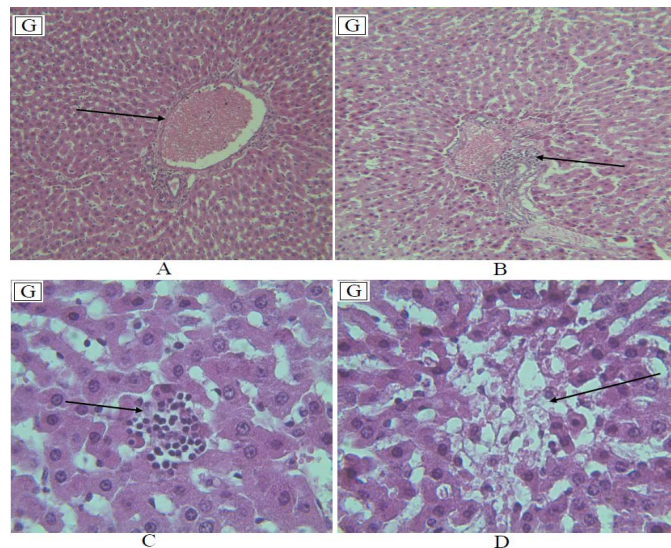


Fig. 7: Optical photomicrograph liver tissue (H & E staining, magnification x 400)



A: hyperemia and congestion of central lobular vein. B: lymphocytic infiltration around the portal space. C: lymphocytic infiltration of tissues D: tissue destruction and irregularity of liver hepatocytes

Fig. 8: Optical photomicrograph of liver tissue (H & E staining, magnification x 400) liver tissue damage in group receiving Gentamicin as 100mg/kg

tissue destruction was observed.

Figure 7 shows photomicrograph of liver tissue slices in C200 that received the cinnamon extract as 200mg/kg B.W.

In G, that received gentamicin alone, tissue destruction along with hyperemia and congestion of centrilobular vein (Part A), lymphocytic infiltration around the portal space (Part B), lymphocytic infiltration of tissues (Part C) and tissue destruction and irregularity of liver hepatocytes (Part D) is observed.

Decrease of necrosis region, congestion and accumulation of inflammatory cells. In GC200 that along with gentamicin, received 200 mg per kg body weight cinnamon extract, their problems were slightly elevated compared to G and in the area of necrosis, congestion and accumulation of inflammatory cells reduced.

DISCUSSION

Gentamicin is one antibiotic that is used a lot. This Drug is used for the treatment of gram-negative bacterial infection in humans and animals. Important complication gentamicin includes hepatotoxicity(2-3). In this study, the reducing effect of cinnamon extract on gentamicin-induced side effects in rat liver was examined. Hepatocytes are complex metabolical liver cells that contain large

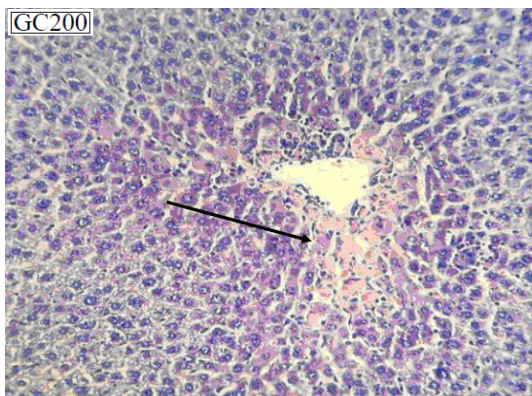


Fig. 9: Optical photomicrograph of liver tissue (H & E staining, magnification \times 400) liver tissue in group GC200 that along with gentamicin received cinnamon extract as 200mg/kg

amounts of enzymes. These enzymes are poured into the plasma due to liver damage, and can be useful for the detection and determination of liver damage. Oxaloacetate transaminase (OT) is microsomal enzyme that is found in large quantities in the liver and is released in the blood. Pyruvate transaminase (PT) is a liver-specific enzymes that exists in cytosol and it is indicator of liver cells as a more sensitive and specific criterion and for liver cell damage. Alkaline phosphatase is present in most tissues and increases as a result of liver diseases. Of course Depending on the type of liver disease, increase of the activity of these enzymes has different values (17-19).

In C200 that received Cinnamon extract, compared to S which received saline solution no significant difference was observed in the activity of liver enzymes including PT, OT, and ALP and also in albumin and protein content. This suggests that in normal conditions, cinnamon extract does not have significant effect on the general condition and in this specific study on the liver. In G that received gentamicin, compared to S which received saline solution, activity of enzymes OT, PT, and ALP were significantly increased.

Followed by that albumin and total protein decreased and this could be indicative of liver injury induced by gentamicin (5). Since albumin and other proteins are produced primarily in the liver, followed by liver injury induced by gentamicin, albumin and other proteins also declined (5). In GC50, GC100 and GC200, that along with gentamicin received different doses of cinnamon extract, roughly proportional to cinnamon extract intake, the damage caused by gentamicin decreased and activity of liver anzymes declined compared to G and in GC200 got close to almost normal levels.

After improvement made, albumin and other proteins also increased. The conducted research indicates antioxidant compounds in cinnamon (20). Researchers know cinnamon antioxidant effect associated with two compounds of eugenol and methyl hydroxy Chalcone. Oral use of eugenol caused glutathione peroxidase activity to be normal and reduced glutathione in normal cells to increase (21). Due to the adverse effects of free radicals and reactions of oxidative stress, presence of the body's antioxidant compounds that can protect from damage caused by oxidative stress seems necessary. Antioxidants have special role in the

prevention and treatment of diseases (22-23). It is also observed in the tissue slices slides and healing effects can be seen in group GC200 group compared to the G100. Therefore, the adverse effects caused

by gentamicin in rats receiving cinnamon extract can be attributed to the antioxidant property of cinnamon extract.

REFERENCES

1. Ayatollahi J., Evaluation of knowledge and activities of medical students in the last two years of their education about chemoprophylaxis following contact with infectious diseases. *IJCID* **9**(26): 54-9 (2005).
2. Stojiljkovic N, Stojiljkovic M., Micromorphological characteristics of the liver and biochemical analyses in the blood of rats treated by gentamicin and verapamil. *Acta medica Medianae* **45**(2): 5-9 (2006).
3. Masakazu K, Yoshiko E, Masashi E., Acquired resistance of *Listeria monocytogenes* in and escaped from liver parenchymal cells to gentamicin is caused by being coated with their plasma membrane. *Microbes and Infection* **16**(3): 237-243 (2014).
4. Nayma S, Sadia C S, MTanveer H P, Jesmine A., Effects of Ashwagandha (*Withania somnifera*) Root Extract On Some Serum Liver Marker Enzymes (AST, ALT) In *Gentamicin Intoxicated Rats* **7**(1):1-7 (2012).
5. Stojiljkovic N, Stojiljkovic M., Micromorphological and histochemical characteristics of a rat's liver treated with gentamicin. *Acta medica Medianae* **45**(3): 24-28 (2006).
6. Wojciech L, Vincent LP., Ternary Complexes of Gentamicin with Iron and Lipid Catalyze Formation of Reactive Oxygen Species. *Chemical Research in Toxicology* **18**(12): 357-364 (2005).
7. Erin E. Battin J., Sulfur and selenium: A Review of reactiveOxygen species scavenging, glutathione peroxidase and metal-binding antioxidant mechanisms. *Cell Biochem Biophys* **55**: 1-23 (2009).
8. Jeffrey WC, Roger GU, Philip GL, Clay TC Acute Hepatocellular Effects of Erythromycin, Gentamicin, and Trospectomycin in the Perfused Rat Liver: Lack of Correlation between Lamellar Body Induction Potency and Cytotoxicity. *Pharmacology & Toxicology* **62**(5): 337-343 (1988).
9. Yu W, Hirotsugu I, Takahito I, Naoko H, Masaya Y., Fetal cells in mother rats contribute to the remodeling of liver and kidney after injury. *Biochemical and Biophysical Research Communications* **325**(3): 961-967 (2004).
10. Yang C, Du X, Han Y., Renal cortical mitochondria are the source of oxygen free radicals enhanced by gentamicin. *Ren Fail* **17**: 21-26 (1995).
11. May YH, Jochen S., Formation of a cytotoxic metabolite from gentamicin by liver. *Biochemical Pharmacology* **40**(11): R11-R14 (1990).
12. Inoue S, Kawanishi S., Oxidative DNA damage induced by simultaneous generation of nitric-oxide and superoxide. *FEBS lett* **371**: 86-88 (1995).
13. Noorolahi Z, Sahari MA, Barzegar M, Doraki N, Naghdi BH., Evaluation Antioxidant and Antimicrobial Effects of Cinnamon Essential Oil and Echinacea Extract in Kolompe. *J Med Plant* **12**(4): 14-28 (2013).
14. Anderson RA, Broadburst CL, Polansky MM, Schmidt WF, Khan A., Isolation and characterization of polyphenol type- A polymers from cinnamon with Insulin-like biological activity. *Journal of Agricultural and Food Chemistry* **52**(1): 65-70 (2004).
15. Khan A, Sfdar M, Ali Khan MM, Khattak KN, Anderson RA, Cinnamon improves glucose and lipids of people with type 2 diabetes. *Diabetes Care* **26**(12): 3215-3218 (2003).
16. Nir Y, Potasman I, Stermer E, Tabak M, Neeman I., Controlled trial of the effect of cinnamon extract on *Helicobacter pylori*. *Helicobacter* **5**(2): 94-97 (2000).
17. Kamath JV, Rana AC, Chowdhury AR., Pro-healing effect of *Cinnamomum zeylanicum* bark. *Phytotherapy Research* **18**(8): 970-972 (2003).
18. Moselhy S, Ali H., Hepatoprotective effect

- of Cinnamon extracts against carbon tetrachloride induced oxidative stress and liver injury in rats. *Biol Res* **42**: 93-98 (2009).
19. Taher M, Ghannadi A, Karimiyan R., Effect of volatile oil extracts of *Anethumgraveolens* I and *Apiumgraveolens* on activity of liver enzymes in rat. *J Qazvin univ med sci* **11**(2): 8-12 (2007).
 20. Kadkhodae M, Khastar H, Arab HA, Ghaznavi R, Zahmatkesh M., Antioxidant vitamins preserve superoxide dismutase activities in gentamicin induced nephrotoxicity. *Transplant Proceed* **39**: 864-865 (2007).
 21. Onderoglu S, Sozer S, Mine Erbil K, Ortac R, Lermioglu F., The evolution of long-term effects of cinnamon bark and olive leaf on toxicity induced by streptozotocin administration to rats. *Journal of Pharmacy and Pharmacology* **51**:1305-1312 (1999).
 22. Van kampen EJ. and Zijlstra WG., Determination of hemoglobin and it's derivatives. *Clinical Chemistry* **8**: 1414-18 (1985).
 23. Peng J, Gones GL, Watson K., Stress protein as biomarkers of oxidative stress: Effects of antioxidant supplement. *Free Radic. Biol. Med* **28**:1598- 606 (2000).