

# An Evaluation Of The Attractiveness Of A Posed Smile With Computerised Variations Of The Smile Parameters

A. RAJA<sup>1</sup>, PRABHURAJ<sup>2</sup> and N. SARAVANAN<sup>3</sup>

<sup>1</sup>Department of Orthodontics, Vinayaga Missions Sankarachariyar Dental College, Salem, India.

<sup>2</sup>Department of Orthodontics, Ultra Dental College, Madurai, India.

<sup>3</sup>Department of Public Health Dentistry, VMS Dental College, Salem, India.

<http://dx.doi.org/10.13005/bpj/537>

(Received: October 03, 2014; accepted: November 20, 2014)

## ABSTRACT

A study was conducted to evaluate the changes in the attractiveness and acceptance of a posed smile with computerised variations of the smile parameters and head types. Two adults, one male and one female were selected. Their posed smile photographs were taken, which were morphed into different images [by using Adobe Photoshop Version 7 and Adobe Photoshop CS2 soft wares]. The judges in our study were educated and uneducated males and females and dental professionals. Results of our study showed that, the smile parameter acceptable for a particular head type was more or less acceptable to the other head types. The overall acceptance of smile parameters showed that an acceptable smile should have minimum buccal corridor space, an upper lip that elevates till the marginal gingiva and a lower lip that is coincident with the upper incisaledges.

**Key words:** Acceptable smile parameters, buccal corridor space, posed smile, Smile arc.

## INTRODUCTION

Harmony between the dominant features of a face contributes to creating a beautiful smile. The dominant features of a face are the facial frame, eyes and the smile with its components - teeth, gingiva and lips. There are two forms of smile - the enjoyment smile and the posed or social smile.

Posed smile gained importance in dentistry and orthodontics mainly because they are repeatable over time. Many researchers like Sheldon peck, Leenapeck, and Ronald J Mackley, Zachrisson<sup>6</sup> and Sarver have evaluated the various parameters of smile which includes upper lip elevation, upper lip curvature, smile arc, buccal corridor space, crown height and gingival exposure in an attempt to analyse the esthetics of smile.

Hence it was felt that there was a need to evaluate the various parameters of smile in the

south Indian population. Orthodontic diagnosis has come a long way and now includes patient driven esthetic diagnosis and treatment planning and hence lay persons were requested to evaluate the smile.

Recent advances with computers and its latest technology have become an essential tool in the research. Different smile images can be created using software from images of natural smile by morphing. The Adobe Photo shop7 and Adobe photo shop CS2 are the softwares which enable to morph and create different images in each chosen parameter with other parameters unchanged. This helps in assessing the importance of each parameter.

## Aims and objectives

The aim of the study was,

1. To analyse the acceptable characteristics of a posed smile.

2. To evaluate the changes in the attractiveness of a posed smile on the basis of computerized variations of the smile parameters.

Many researchers including Sheldon Peck, Bjorn Zacchrisson, David Sarver and James Ackerman have proposed various acceptable parameters for esthetic smile. It is a well known fact that esthetic perception for smile could differ among dentists and lay persons. It was also necessary to find out whether the acceptable parameters for esthetic smile in one head type are acceptable for the other head types. Hence it was felt that there was a need to evaluate how dental professionals and lay people judge these parameters.

#### **Review of literature**

Ernst K. Janzen (1977)<sup>8</sup> advocated careful clinical inspection of the patients smile before treatment to achieve a well balanced smile.

Peck et al (1992)<sup>4</sup> did a study to examine the nature of gingival smile. The results indicated that the capacity to project a gingival smile line was related to anterior vertical maxillary excess and muscular ability to raise the upper lip significantly higher than average when smiling.

Ronald J. Mackley (1993)<sup>5</sup> evaluated smiles before and after orthodontic treatment and concluded that to maximize the potential for improving a patient's smile, we must consider moving anterior teeth vertically.

Bjorn U Zachrisson (1998)<sup>6</sup> discussed the esthetic factors involved in tooth display in normal conversation and smiling. He advocated to reduce the excessive gingival display in a long faced patient by active maxillary incisor intrusion coupled if necessary with labial gingivectomies.

Marc and James Ackerman (2002)<sup>3</sup> considered smile analysis and smile design as the key elements of orthodontic diagnosis and treatment planning. They proposed the use of digital video and computer technology for evaluating the patients dynamic anterior tooth display and also to incorporate smile analysis into routine treatment planning.

Sarver and Ackerman (2003)<sup>2</sup> in the first part of the article discussed the evaluation of smile analysis and reviewed the dynamic records needed. In the second part, they reviewed smile analysis and treatment strategies.

Theodore Moore et al (2005)<sup>10</sup> conducted a study to determine the influence of buccal corridors on smile attractiveness when judged by lay persons. Results showed that having minimum buccal corridors is a preferred esthetic feature in both men and women and large buccal corridors should be included in the problem list during orthodontic diagnosis and treatment planning.

Roy Sabri (2005)<sup>11</sup> reviewed the eight major components of smile and discussed their impact on orthodontic diagnosis and treatment planning. They advised that these should not be considered as rigid boundaries, but as artistic guidelines to help orthodontists treat individual patients, who are today more highly aware of smile esthetics.

#### **MATERIAL AND METHODS**

##### **sample selection:**

The study was conducted in the Department of Orthodontics and Dentofacial Orthopedics, at Vinayaga Missions Sankarachariyar Dental College and Hospital, Salem. Two adult subjects, one male and one female (aged 21 years and 24 years respectively) having acceptable smiles and without history of any orthodontic treatment were selected.

##### **Method for obtaining image:**

Digital photographs of the samples in a relaxed social smile position were taken by using Nikon coolpix model no: S210 digital camera. The camera was fixed on a tripod. The captured images were transferred to personal computer Compaq Intel Pentium 4 with 15 inch colour monitor. The images were manipulated using Adobe Photoshop Software Version 7 and Adobe Photoshop CS2. These softwares have built in features for modifying the images. The images were modified by altering upper lip elevation during smile, upper lip curvature during smile, smile arc, buccal corridor, crown height during smile.

The handouts were shown to a panel of judges consisting of 20 educated males , 20 uneducated males , 20 educated females , 20 uneducated females and 20 dental professionals .The judges were asked to critically evaluate and examine each of these photographs and rate them according to the following facial attractiveness rating chart

Thus each photograph received a particular score from each of the panel members.

**Statistical analysis**

The photographs with the highest scores were then chosen amongst each group and submitted to find out the mean and standard deviation.Statistical comparison using the Analysis of Variance (ANOVA) test was done for comparison between all groups .Scheffe’s test for multiple comparison and impaired students ‘t’ test for comparison between male and female samples with respect to each group was done

It was found that the highest ratings were given to image wherein lower lip was just touching and parallel to the incisal edges of uper incisors. Thus, our study shows similar results to that of Hulsey, Sarver and Ackerman<sup>7</sup>

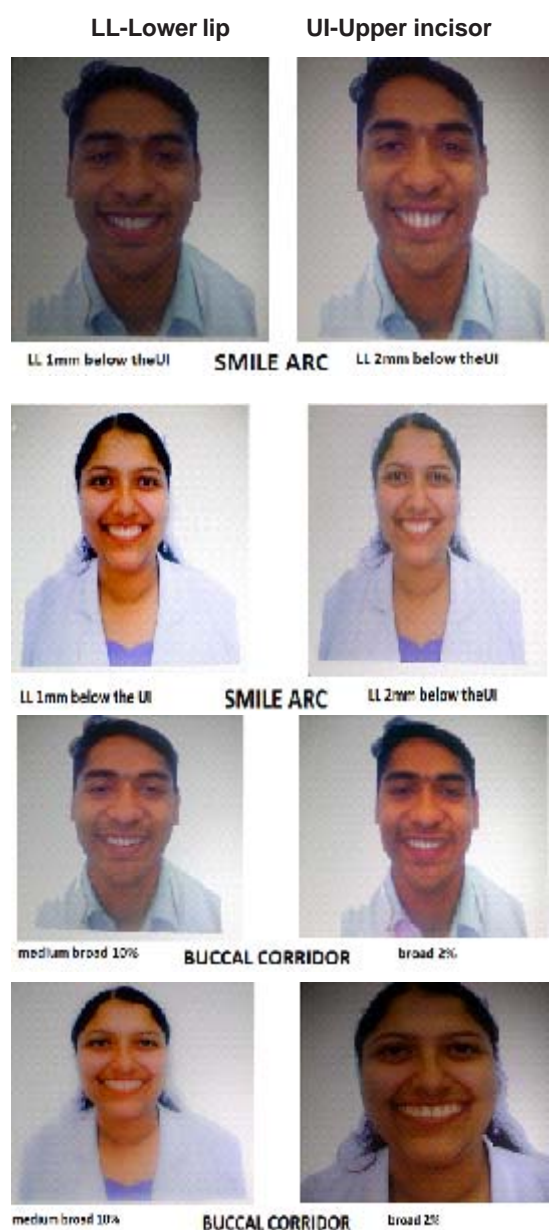
In our study, we classified images into 5 viz- 2% 10% 15% 22% and 28% as was done by Moore . It was found that the highest ratings were given to minimal of buccalcorridor ie., (10% of lateral negative space) rather than no buccal corridor space , which agrees with Moore’s study .<sup>10</sup>

Highest ratings were given for 10mm of crown height for male and 9mm of crown height for female on a posed smile.

An exposure of inter - dental papilla with a slight amount of marginal gingiva was considered as esthetically more acceptable

For upper lip elevation of 8 mm during smile,a very highly significant difference was found between the ratings of educated males, educated and uneducated females.A very highly significant difference was found between the ratings of uneducated males compared with all other groups

for more upward curvature of upper lip during smile . For smile arc wherein lower lip was kept slightly touching upper incisors, a very highly significant difference was found between the ratings of uneducated females and dental professionals. A very highly significant difference was found between the ratings of dental professionals and other judges for smile arc wherein lower lip was placed 1mm below upper incisors.For a medium broad (10%) buccalcorridor,a very highly significant difference was found between the ratings of educated



males, uneducated females and dental professionals.

in mind not to alter the acceptable parameters of the smile as given above.

### DISCUSSION

Facial appearance often plays a strong role, especially in the initial stages of acquaintance. The orthodontic profession has always been in pursuit of the ideal dentition. A century ago the orthodontic paradigm was geared toward achieving optimal proximal and occlusal contacts of the teeth within the framework of a balanced profile. When cephalometrics based diagnosis and treatment planning hit full stride in the 1950s and 1960s, esthetics in orthodontics was defined primarily in terms of the profile. The present emphasis is towards enhancing facial esthetics and creating a beautiful smile.

#### Clinical implications of the study:

Whenever we examine a patient pretreatment or during treatment we should keep

#### Facial Attractiveness Rating Chart:

Score	Rating
1	Poor
2	Fair
3	Good
4	Very Good
5	Excellent

Upper lip elevation of 7 to 8 mm holds good only for the patients who have a sufficient upper lip length, the average lip length being 23mm for males and 20mm for females. When upper lip length and mobility of the lip are normal, a gingival smile with excessive incisor display at rest can be attributed to vertical maxillary excess.

A short upper lip should not be treated by shortening the maxilla unless the facial outline can accommodate such a change. If a gingival smile is caused by a hypermobile upper lip, it would be a mistake to correct it with maxillary impaction surgery, because that would result in little or no incisor display at rest and thus make the patient look older. Excessive lip elevation should therefore be recognised as a limiting factor.

Upper lip curvature is a muscle driven position. Hence, it cannot be subjected to alteration by orthodontic treatment. Over intrusion of maxillary incisors may flatten the smile arc, if the lower lip position is not kept in mind. A short crown can be congenital or due to attrition. It can also be due to gingival hyperplasia. If there is little or no incisor display at rest the crown height can be increased.

#### Smile parameters preferred by the different group of judges

	Upper Lip Elevation	Upper Lip Curvature	Smile Arc	Buccal Corridor	Crown Height	Gingival Exposure
Educated Males	8mm	straight	LL touching UI	Broad	Male -10mm Female -9mm	IDP with slight MG
Uneducated Males	7mm	straight	LL touching UI	Medium Broad	Male -10mm Female -9mm	IDP with slight MG
Educated Females	7mm	Down wards	LL touching UI	Medium Broad	Male -10mm Female -9mm	IDP with slight MG
uneducated females	8mm	Downwards	LL touching UI	Medium Broad	Male -10.5mm Female -9.5mm	IDP with slight MG
Dental Professionals	7mm	Straight	LL touching UI	Medium Broad	Male -10mm Female -9mm	IDP with slight MG

IDP — Inter dental papilla

LL — Lower lip.

MG — Marginal gingiva

UI — Upper incisors.

**CONCLUSION**

According to our study, an acceptable posed smile should have the following characteristics.

1. An upper lip elevation of 7 to 8 mm, higher lip elevation being more acceptable for

females.

2. Upper lip curvature straight or slightly downwards
3. Lower lips just touching and parallel to the incisal edges of upper incisors.
4. Minimal buccal corridor space
5. Exposure of interdental papilla with a slight amount of marginal gingiva

**REFERENCE**

1. Tatarunaite E, Playle R, Shaw W, Richmonds. Facial attractiveness: A longitudinal study – *AJO DO* : **127**: 676 – 682 (2005).
2. Sarver D, Ackerman M. Dynamic smile visualization and quantification : Part 1 : Evolution of the concept and dynamic smile capture . *AJO DO* : **124** :4-12 (2003).
3. Ackerman MB and Ackerman J2 . Smile analysis and design in the digital era . *JCO*: **36** (4) 221 – 236 (2002).
4. The gingival smile line – *Angle orthod* : **62** (2) : 91 — 100 (1992).
5. Mackley RJ . An evaluation of smiles before and after orthodontic treatment . *Angle ortho*: **63** : 183 – 190 (1993) .
6. Zachrisson BU .Esthetic factors involved in anterior tooth display and the smile . Vertical dimension . *JCO* : **32** (7) : 432 – 445 (1998).
7. Sarver DM . The importance of incisor positioning in the esthetic smile : The smile arc . *AJO DO* : **120** : 98 – 111 (2001).
8. Javizen EK . A balanced smile – A most important treatment objective . *AJO DO* : **72** (4) : 359 – 372 (1977)
9. Sarver D and Ackerman M. Dynamic smile visualization and quantification : Part 2 . Smile analysis and treatment strategies. *AJO DO* ; **124**:116-127 (2003)
10. Moore T, Southard KA, Casco JS, Qvan F, Southard TE .Buccal corridors and smile esthetics. *AJO DO* : **127** : 208 - 213 (2005).
11. Sabri. R. Overview : The eight components of a balanced smile . *JCO* : **39** (3) : 155 - 167 (2005) .
12. The esthetics of the smile : A review of some recent studies . *Int. J. Prosthodont* : **12** : 9 - 19 (1999) .