

Effect of Oxydemeton Methyl Toxin on Changes of Testis Histopathology and body Weight in Male Rats

SYAHMARD NAHID^{1*}, PARIVAR KAZEM¹, SHARIATI MEHRDAD¹, AZHDARI SARA², ZARE AFSHIN¹, MOHAMMADI SAHAR², FARZAM MOHSEN¹ and FARZAM MOHAMMAD¹

¹Department of Physiology, Medical School, Kazerun Branch, Islamic Azad University, Kazerun, Iran.

²Department of Clinical Biochemistry, Kermanshah University of Medical Sciences, Kermanshah, Iran.

*Corresponding author E-mail :dr.syahmard@yahoo.com

DOI: <http://dx.doi.org/10.13005/bpj/609>

(Received: April 12, 2015; accepted: June 19, 2015)

ABSTRACT

Every year lots of different pesticides through various ways go to the environment . These pesticides are distributed to the environment and transported to the remote areas . To predict the effects of these substances on the ecosystem, in addition to information on their toxicity, how to enter, play and behavior of these compounds in nature should be well known . The purpose of this study was to determine the effect of oxydemeton methyl toxin on body weight changes and testis tissue changes in rats. For this purpose, 40 adult male Wistar rats, weighing approximately 190 ± 10 gr were divided into 5 groups of 8 . The groups include : Control group , sham and treatment with doses 2ppm , 5ppm , 10ppm . Toxin was fed to the animals orally daily for 14 days . At the end of experimental period , animals were weighed , and animal's testis for examining of tissue changes removed from body and weighed and after the tissue sections were prepared and stained with hematoxylin – eosin, they were studied and examined. This toxin in any of levels does not make significant effect on body weight and testicular weight of animals . Histological studies showed that treatment group with maximum amount of toxin has decrease of sperm density compared with control group $P<0.05$. Probably this toxin with effect on hormone testosterone and secretion decrease of this hormone causes weight decrease and also testis tissue changes specially in high doses of toxin.

Key words: Oxydemeton methyl , Body weight , Testis tissue , Male rat.

INTRODUCTION

Humans by making chemical pesticides have been decided to control their environment in order to keep safe agricultural crop from harmful pests . The dating of chemical fight with pests and plant disease back over a thousand years before Christ¹ . More pesticides are sensitive on the nervous system and it is specified that nervous system controls body and so it will be easy targets for chemical attacks . These compounds are usually very effective and works quickly . Pesticides have different positions in nervous system and its constituent units of neurons . It consists of axons, the neural groove, and receptors² . Despite the deleterious effects of pesticides on the environment and other living things, unfortunately, currently the

most effective and perhaps the only practical way to control pest is the use of chemical pesticides . That such toxin are chemical compounds called organophosphates that used in agriculture, industry, horticulture, veterinary and home^{3, 4} . In Iran these compounds as the third leading toxicity and the cause of poisoning deaths have been reported⁵ . These compounds irreversibly cause serine phosphorylated in the active site of enzyme Cholinesterase that with inhibiting this enzyme and accumulation of acetylcholine , cause cholinergic crisis^{3, 4} . Important first step in the construction of new phosphorus pesticides was done by German chemist Gerhard Schrader in 1934 . But after World War II, these compounds were employed in agriculture¹ . These compounds unlike organic chlorinated pesticides can not accumulate in the

tissues of living organisms and life cycles¹. Today, Negative views to pesticides is very serious and it's very natural because killing pests is what to expect from pesticides, But its negative effects is unexpected and more attention is being, Especially in Iran pesticides in general are called poison, and it can cause more severe reactions, So that if we want to write the benefits of pesticides, we fear to blame for supporting the use of chemical pesticides to control pests, If we have more information about pesticides and transmit this information to notify consumers And to teach them how, when, what, where and how much to apply pesticide and warn them overuse we will have better results⁶. Oxy dimethyl toxin with brand name metasystux-R, more than 85-90% are Phosphoinositide thiol that 10-15% of it is not known yet. There are different combinations of demeton with features and various formulas⁷. Possible side effects of using this toxin can be as follow: Increased eye secretion, increased salivation, diarrhea, coughing and breathing slow (difficult breathing), vomiting, abdominal twist, anesthesia, congestion throughout the body, Bleeding in cardiac, bleeding in the stomach, intestine congestion and inflammation, pulmonary edema, pulmonary high secretion and high salivary secretion⁷. In the present study the effect of oxy dimethyl toxin on testis tissue changes and also body weight of male rats were examined so to be aware of potential side effects of these toxins on the male reproductive system.

MATERIALS AND METHODS

This study is experimentally and completely random. All ethic about laboratory animals have been done. 40 Wistar male rats weighing $190 \pm 10\%$ gr and age of 2/5-3 month were provided from the breeding center of laboratory animals of Islamic Azad University of Kazeroon branch. Rats were placed in animals house in Kazeroon Islamic Azad University for 14 days in laboratory conditions including temperature of $20 \pm 5^\circ \text{C}$ and cycle of 12 hours light and 12 hours dark. The Rats were kept in cages with metal mesh doors and were using standard diet (pellete). Water with especial glass bottles were giving to them. Cage 3 times a week was disinfected with 70% alcohol. Method of preparation and administration of the oxydemeton methyl is as follow

. Main solvent is water and in this research preferably used distilled water and were prescribed orally^{8,9,10}. Therefore, each animal was considered a dark glass container. In order to reduce the error probability, poison were weighed daily and with 2 ml of distilled water was poured into a glasses. Toxin was fed to the animals with especial needle. The rats were divided randomly into 5 groups of 8 that include:

- 1- Control group (A), includes 8 animals that did not receive any treatment, but all conditions were similar to other groups.
- 2- Injection group (B), includes 8 animals that daily 2 ml of distilled water received orally.
- 3- Experimental group with the minimum amount of toxin (C¹), including 8 animals that daily 2 ppm oxydemeton methyl toxin dissolved in distilled water with the final volume 2 ml received orally.
- 4- Experimental group with a moderate amount of toxin (C²), including 8 animals that daily 5 ppm oxydemeton methyl toxin dissolved in distilled water with the final volume 2 ml received orally.
- 5- Experimental group with a maximum amount of toxin (C³), including 8 animals that daily 10 ppm oxydemeton methyl toxin dissolved in distilled water with the final volume 2 ml received orally.

After 14 days period, rats of all groups after weighing were anesthetized by ether and then right and left testis of animals for examining tissue changes removed from the body and weighed, and after preparation tissue sections and staining with hematoxylin – eosin, were studied. One-way ANOVA for comparison between treatments and followed by t-test and Duncan test was used for multiple comparisons between groups. ($P < 0.05$) was significant level. Data analysis and statistical testing was performed using SPSS, version 17.

RESULTS

In this section, changes of body weight in the experimental groups, control and sham in the beginning and end of experiment have been compared. The mean body weight between different groups and control group in the first day and end

day of experiment , according to tables and related charts , did not show significant change in the $P < 0.05$ level .Thus , It can be concluded that different amounts oxydemeton methyl for 14 days , did not show significant effect in $P < 0.05$ level on the body weight of animals under study (Table 1) . According to Table 1, significant difference in the $P < 0.05$ level in comparison mean of the right testis weight between control group , sham group , and experimental groups was not found (table 1) . According to Table 1, significant difference in the $P < 0.05$ level in comparison mean of the left testis weight between control group , sham group , and experimental groups was not found . Images 1 to 5 show cross-sections of testes in different groups .

DISCUSSION

The results from Table 1 indicate that oral administration of oxydemeton methyl at doses of minimum (2ppm), medium (5ppm) and maximum (10ppm), at the end of 14 days , Significant changes in weight of the animals in the experimental groups , compared to control and sham groups and also to each other have not created , But there is a slight reduction in body weight of the animals , which may be due to effect of oxydemeton methyl on the concentration of hormones testosterone, cortisol and thyroxine . Studies show that growth hormones , thyroxine, glucocorticoids and sex hormones are among the factors that can be effective on Fat

Table 1 : Mean concentrations of hormones testosterone and dihydrotestosterone changes in different experimental groups

	Mean body weight (gr)	Mean right testis weight (gr)	Mean left testis weight (gr)
Control	208/2±7/60	1/32±0/02	1/35±0/06
Sham	210±6/62	1/32±0/06	1/32±0/03
Minimum amount of toxin 2ppm	206/4±8/42	1/29±0/07	1/29±0/04
Moderate amount of toxin 5ppm	208/3±7/45	1/30±0/01	1/28±0/02
Maximum amount of toxin 10ppm	205/8±10/12	1/29±0/05	1/30±0/01

Significant difference is $P < 0.05$ level and the number of samples in each group is $n=8$. The sign of * indicate a significant difference with the control group

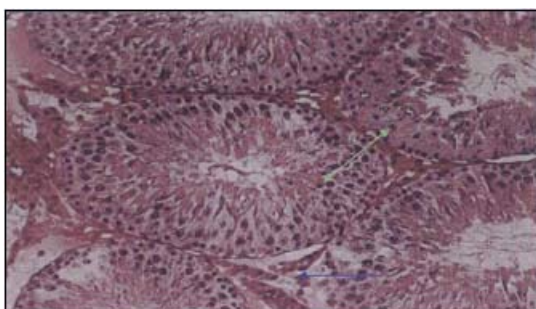


Fig. 1 : Photo micrograph of Seminiferous tubules in control group with magnification of (100x) and stained with hematoxylin – eosin . primary spermatocytes cells in ratio basement membrane are chains and regular And spermatozoa cells have also high density . (The green arrows are Seminiferous tubules and the blue arrows are interstitial spaces .)

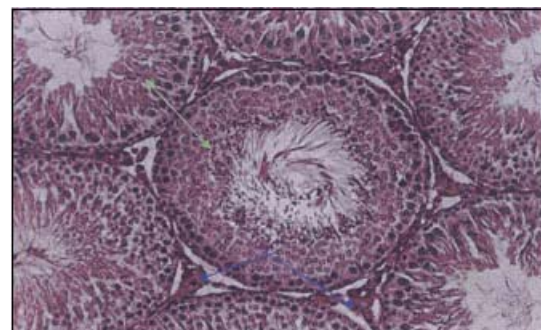


Fig. 2 : Photo micrograph of Seminiferous tubules in sham group with magnification of (100x) and stained with hematoxylin – eosin . Perceptible change in the density of the cells , how placing spermatogonia cells in ratio basemen membrane , spermatocytes cells, spermatogonia, and leydig cells does not found. (The green arrows are Seminiferous tubules and the blue arrows are interstitial spaces .)

accumulation and increase muscle mass in the body¹¹. But the decrease of androgen receptors and reduce the concentration of testosterone due to consumption of oxydemeton methyl, anabolic proteins synthesis and thus muscle size reduces^{12,13}

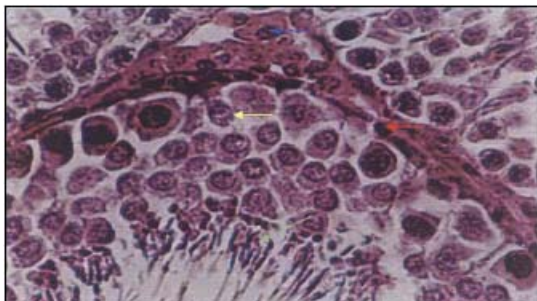


Fig. 3 : Photo micrograph of Seminiferous tubules in experimental group with minimum amount of toxin with magnification of (400x) and stained with hematoxylin – eosin . Perceptible change in the density of the cells , how placing spermatogonia cells in ratio basement membrane , spermatocytes cells, spermatogonia, and leydig cells does not found . (Green arrow indicates density of spermatozoon , blue arrow indicates leydig cells , red arrow indicates spermatogonia and yellow arrow indicates primary spermatocytes)

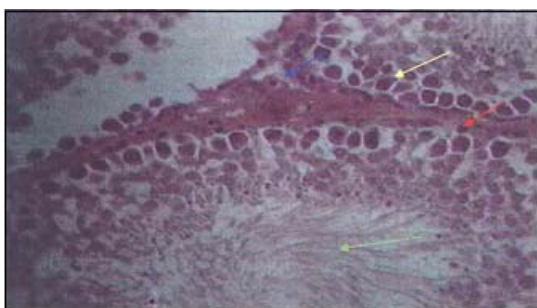


Fig. 4 : Photo micrograph of Seminiferous tubules in experimental group with moderate amount of toxin with magnification of (400x) and stained with hematoxylin – eosin . Perceptible change in the density of the cells , how placing spermatogonia cells in ratio basement membrane , spermatocytes cells, spermatogonia, and leydig cells does not found . (Green arrow indicates density of spermatozoon , blue arrow indicates leydig cells , red arrow indicates spermatogonia and yellow arrow indicates primary spermatocytes)

. However, the increase of the cortisol induced consumption of oxydemeton methyl , also cause increase of lipolytic and proteolytic processes , and resulting in weight loss^{14, 15, 16} . Oxy dynton methyl in high doses causes decrease of thyroxine hormone^{17, 18} this hormone has a catabolic effect on adipose tissue and muscle, so at adipose tissue stimulates lipolysis and in muscle tissue increase Protein decomposition , Thus, by reduction in thyroxine induced consumption of oxydemeton methyl, above effects would decrease and so weight loss may be adjusted ; On the other reduction of thyroxine , increase the amount of SHBG^{20, 19} and decreases testosterone²¹ and a reduction in body weight may be indirect . Finally it can be say that significant weight loss has not been created . According to the results of table (1) , oral consumption of oxydemeton methyl with amount of minimum , medium , and maximum in experimental groups , has not significant influence on the weight of the right and left testis . The results of this research show that administration of minimum and medium of oxydemeton methyl toxin for 14 days in male rats , Remarkable change in how to get spermatogonia cells in ratio basement membrane , arrangement and number of spermatocytes cells and density of Spermatozoon and sertoli and leydig cells compared to control group does not make (figure 3

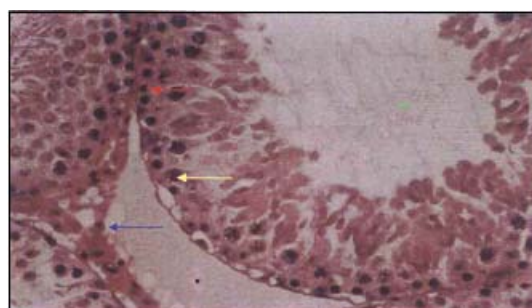


Fig. 5 : Photo micrograph of Seminiferous tubules in experimental group with maximum amount of toxin with magnification of (400x) and stained with hematoxylin – eosin . Irregular cells, reducing the number of Leydig cells and spermatozoa in the lumen is considerable . (Green arrow indicates density of spermatozoon , blue arrow indicates leydig cells , red arrow indicates spermatogonia and yellow arrow indicates primary spermatocytes)

to 4) . But in the treatment group with the maximum amount of toxin little changes in sperm density compared to the control group can be observed (figure 5) . In the previous researches stated that oxydemeton methyl toxin causes reduction of testosterone^{12,14,15,16,22,23} . Testosterone is survival factor for spermatogenesis and evolution of spermatid especially in the late stages strongly depend on testosterone and FSH²⁴ , FSH and testosterone activity in the final stages of spermiogenesis in rats increases²⁵, Synergistic effect of FSH and testosterone activity on Sertoli cells to support spermiogenesis , by increasing intracellular calcium levels is justified²⁶. So probably decrease of testosterone resulting from consumption of oxydemeton methyl toxic , impaired in spermatogenesis and decrease of sperm density in the lumen will follow . Furthermore, according to the research, testosterone and DHT stimulate protein production in male accessory organs and One of the major proteins in the above organs, is the protein binding to androgen (ABP) , These hormones by increase transcription of the gene ABP, the amount of mRNA coding for this protein may increase , this glycoprotein is secreted into the

seminiferous ducts and its role is binding to testosterone , thus , produced testosterone by leydig cells with high concentration to the site of Spermatozoon transferred , this step is crucial because certain normal level of testosterone in the blood is not able to support Seminiferous and is required more amount of this hormone,²⁷ so , decrease in hormone testosterone can impair spermatogenesis and sperm density may reduce .

CONCLUSION

According to the results it can be stated that high doses of oxydemeton methyl may decrease the hormone thyroxine . This hormone has catabolic effect on adipose tissue and muscle, so the adipose tissue stimulate lipolysis and in the muscle tissue increases protein decomposition , thus, a reduction in thyroxine resulting from consumption of oxydemeton methyl , above effects decrease and probably weight loss can be done . The toxin with the effect on secretions of the hormone testosterone and decrease secretion of this hormone , causes damage testicular tissue in the maximum dose.

REFERENCES

1. Rakhshani E, Talebi AA, Taheri AH. Principles of toxicology agricultural. 2th ed. Tehran: Publications dictionary; 2006. (in Persian)
2. Iustin VT, Toshio N. Potent Modulation of Tetrodotoxin-Sensitive and Tetrodotoxin-Resistant Sodium Channels by the Type II Pyrethroid Deltamethrin. *the journal of pharmacology and experimental therapeutics*, **284** (3): 958- 965 (1998).
3. Senanayak, N., Johnson, R. Acute polyneuropathy after poisoning by a new Organophosphate insecticide. *N engle j med*. **302**: 155-157 (1992).
4. Zhang, CH., Malhorta, SV. Increased paraxon detection by acetylcholine esterase inactivation with ionic liquid additives. *Talanta*. **67**: 560-563 (2005).
5. Abdollahi, M., Mostafalou, S., Pournourmohammadi, S., Shadnia, S. Oxidative stress and cholinesterase inhibition in salvia and plasma of rats following subchronic exposure to malathion. *Comp biochem physiol*, **137**: 29-34 (2004).
6. Mousavi MR. Pesticides and their use (insecticides and pesticides). 1 th ed, Frontiers of knowledge, Abnegah, Tehran: 2010; p 19- 310.
7. Arjangi s . Guide the use of pesticides and chemical principles of safety against pests and plant diseases. Of parks and green space, **1391** ; s 1-5 .
8. Meyer, DC. Eadens, DJ. The role of endogenous serotonin in phasic LH release, **15**: P:283-286 (1985).
9. Khodam , R. The generic drugs, Didavr Press, Third edition, Tehran, s:310-330 (1382).
10. Katzong , terror. Basic and Clinical Pharmacology, Tamerlane Publisher, s:420-487 (1381).
11. Shohn, EH. Wolden-Hanson, T. Matsumoto, AM. Testosterone (T)-induced changes in

- arcuate nucleus cocaine-amphetamine-regulated transcript and NPY mRNA are attenuated in old compared to young male brown Norway rats: contribution of T to age-related changes in cocaine-amphetamine-regulated transcript and NPY gene Expression *Endocrinology*, **143**: P:954-663 (2002).
12. Gromo, U. J. Weinbauer, G.F. Sinioni, M. Nieschlag, E. Effects of antiandrogens and ethane dimethane sulphonate (EDS) on gene expression, free subunits, bioactivity and secretion of pituitary gonadotrophins in male rats, *Mol. Cell. Endocrinol.* **9**: P:119-125 (1993).
 13. Canosa, L.F. Ceballos, N.R. Effects of different steroid-biosynthesis inhibitors on the testicular steroidogenesis of the load *Bufo arenarum*, *J comp Physiol.* **171**: P:519-526 (2001).
 14. Sciarra, F. Toscano, V. Concolino, G. Di Silverio, F. Antiandrogens: clinical applications, *J. Steroid. Biochem. Mol. Biol.* **20**: P:349-362 (1999).
 15. Shen, R. Lin, M.C. Sadeghi, F. Swerdloff, R.S. Rajfer, J. Gonzalez-Cadavid N.F. Androgens are not major down-regulators of androgen receptor levels during growth of the immature rat penis *J. Steroid. Biochem. Mol. Biol.* **57**, P:301-13 (1996).
 16. Subhedar, N.K. Androgenetic Alopecia in men and women: an overview of cause and treatment, *Endocrine*, **28**: P: 165-170 (2005).
 17. Lagu, S.K. Bhavsar, N.G. Sharma, R.K. Ramachandran, A.V. Neonatal hypothyroidism- induced changes in testis size, dependence on temperature, *Neuro. Endocrinol. Lett.* **28**: P:780-788 (2005).
 18. Ronald, M. Lechan, T. Functional anatomy of the hypothalamus and pituitary, P:150-158 (2004).
 19. Pinos, H. Panzica, G.C. Vigliani-Panzica, C. Sica, M. Gotti, S. Martini, M. Carrillo, B. Collado, P. Effects of gonadal hormones on central nitric oxide producing systems *Neuroscience*, **138**: P:987-995 (2006).
 20. Przekop, F. Tomaszewska-Zaremba, D. Mateusiak, K. The involvement of GABA(A) receptors in the control of GnRH and beta-endorphin release, and catecholaminergic activity in the ventromedial-infundibular region of hypothalamus in anestrus ewes, **52**: P:489-500 (2007).
 21. Collu, R. Du Rusisseau, P. Tache, Y. Role of putative neurotransmitters in prolactin, GH and LH response to acute immobilization stress in male rats, *Endocrinol J*, **23**: P:281-7 (1996).
 22. Mahoudeau, J.A. Corvot, P. Valcke, J.C. Menard, J. Bricaire, H. Antiandrogenic effect of Oxymetone methyl, *Ann. Endocrinol.* **37**: P:57-58 (2001).
 23. Sabbieti, M.G. Marchetti, L. Menghi, G. Yamamoto, K. Kihuyama, S. Vaudry, H. Polzonetti-Magri, A. Occurrence of beta-endorphin binding sites in the pituitary of the frog *Rana esculenta*: effect of beta-endorphin on luteinizing hormone secretion *Gen. Co. Endocrinol.* **132**: P:391-398 (2003).
 24. Marias, J.R. Malloy, V.L. Orentreich, N. Synergistic antiandrogenic effects of topical combinations of 5 alpha-reductase and androgen receptor inhibitors in the hamster sebaceous glands, *J. Invest. Dermatol.* **91**: P: 429-433 (1999).
 25. Wang, J.M. McKenna, K.E. Lee, C. Determination of prostatic secretion in rats: effect of neurotransmitters and testosterone *Prostate*, **18**, P:289-301 (2001).
 26. Asa Sylvania, L. Pituitary histology in man, *journal of pharmacology*, **167**: P:353-622 (2002).
 27. Harper, M. *Biochemistry*, Samat Press, second edition, Tehran s:287-320 (1380).