

Postauricular Advancement Flap for Closure of Persistent Mastoid Cutaneous Fistula

NADER SAKI, SOMAYEH ARAGHI, HASSAN ABSHIRINI and SOHEILA NIKAKHLAGH

Hearing & Speech Research Center, Ahvaz Jundishapur University of Medical Sciences, Ahvaz, Iran

*Corresponding author E-mail: nikakhlagh.s@gmail.com

DOI: <http://dx.doi.org/10.13005/bpj/785>

(Received: August 15, 2015; accepted: September 20, 2015)

ABSTRACT

Postauricular cutaneous mastoid fistula is a rare complication of chronic otitis media, complicate ear surgery and, very rarely congenital cholesteatoma. The failure rate with simple closure is high due to necrotic skin edge. Therefore Several surgical techniques for closure of the this fistula have been described A 45-year-old woman with postauricular mastoid cutaneous fistula after canal wall down mastoidectomy was underwent fistula tract resection and fascio-cutaneo-periosteal advancement flap repair. She has been followed up for six months with no recurrence. Postauricular advancement flap is effective for closure of persistent cutaneous mastoid fistula.

Key words: Mastoid cutaneous fistula, Cholesteatoma, Mastoidectomy, Flap.

INTRODUCTION

Postauricular mastoid cutaneous fistula is an unusual complication of chronic otitis media (COM) and a rare complication of cholesteatoma. Post-aural discharge and cosmetic applications are the two complications that often need medical assistance for closure. Post auricular mastoid cutaneous fistula is commonly unilateral, but bilateral occurrence complicating cholesteatoma has been reported¹. The inverted skin surrounding the fistula often demonstrates necrosis, with epithelial migration and fusion with epithelial lining of the mastoid cavity, somastoid cutaneous fistulas tend to heal very slowly, or not at all. Therefore it doesn't tend to heal spontaneously and surgical closure is indicated.

Several surgical techniques have been proposed for closure of mastoid cutaneous fistulas. These techniques including simple closure, bone or cartilage graft, and muscle flap coverage. The

failure rate of simple closure approach is high due to necrotic skin edge. Similarly, the bone and cartilage graft techniques are usually accompanied by resorption and infection making them unsatisfactory. In addition, muscle flap can undergo denervation atrophy^{2,4}. Some techniques such as Vira and Andrew technique may not be applicable where conchal cartilage is already used in previous tympanomastoidectomy that is complicated by postauricular mastoid cutaneous fistula³.

Postauricular mastoid cutaneous fistula is rare and it is difficult to prescribe any technique as one-size-fits-all for all cases of mastoid cutaneous fistula. The Abiodun Daud Olusesi technique was used posteriorly based fascio-cutaneo-periosteal advancement flap for closure of Post auricular mastoid cutaneous fistula, which resolves this problem and Andrew technique problem². We describe a simpler modification of this technique in our study.

Case Report

A 45-year-old woman with right COM and concomitant cholesteatoma for 10-year duration is described in this report. She had meatoplasty and canal wall-down mastoidectomy. She developed right postauricular discharging cutaneous mastoid fistula (Fig. 1) 2 months after surgery, which did not heal with conservative treatment.

The patient underwent fistula tract resection and fascio-cutaneo-periosteal advancement flap repair. After general anesthesia and after replacing the patient in appropriate position and prep and drape, lidocaine – epinephrine 1/100000% solution was injected in post auricular region in the place of incision. An elliptical incision was made around the fistula at the post-auricular groove and fistula tract dissected out completely with direct vision by using microscope. (Fig. 2). then an advancement flap from post auricular by two horizontal incisions in the plane of subperiosteal was raised and undermined from the periphery (Fig. 3). To reduce tension over the wound margins with far and near sutures wound margins, especially in postauricular groove, was closed (Fig. 4).

RESULTS

This technique has been successfully used in Our Case. She was a 45-year-old woman with Post auricular mastoid cutaneous fistula after canal wall down mastoidectomy. She has been followed up for 6 months and no reoccurrence was observed.

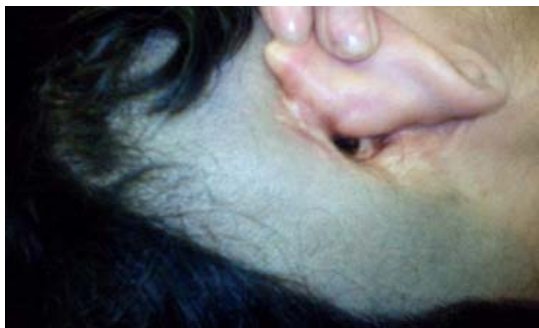

Fig. 1: Postauricular cutaneous mastoid fistula

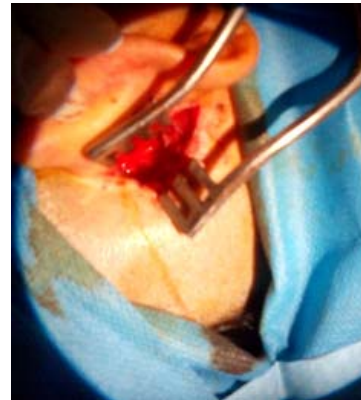

Fig. 2: Fistula tract dissected out completely

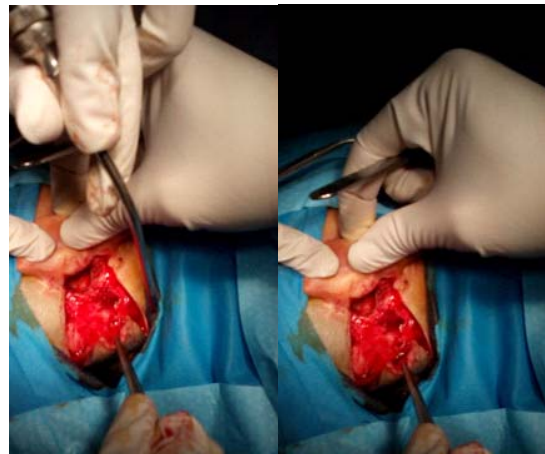


Fig. 3: A post auricular advancement flap

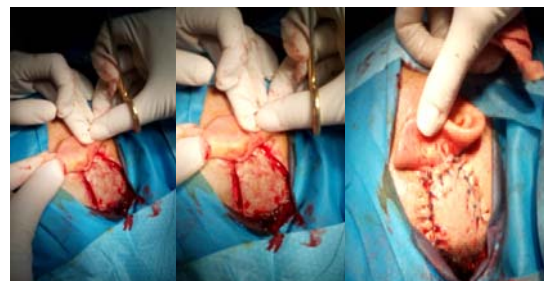

Fig. 4: Closure of the wound

DISCUSSION

This technique is simpler than most previously described even Abiodun Daud Olusesi technique², can be done especially in cases of fistula complicating repeated mastoid surgery, where the postauricular skin is usually thickened

and fibrosed. Unlike the technique of Vira and Andrew³, the cartilage is not compromised using this technique, and it can be used in cases where conchal cartilage has already been used for previous tympanoplasty. Another advantage of this technique is that it can be carried out under local or general anesthesia

This technique provides an addition to the few techniques already described for closure of persistent cutaneous mastoid fistula.

CONCLUSION

Because of rarity of persistent mastoid cutaneous fistula in an our practice, making it unlikely to have enough broad expertise to pronounce best surgical option for all mastoid-cutaneous fistulas, our technique represents an addition to techniques already described, and should be considered for its simplicity for fistulas.

REFERENCES

1. Bhat KV, Udayashankar SG, Venkatesha BK, Kumar P. Bilateral atticofacial chronic suppurative otitis media presenting as bilateral cutaneous mastoid fistulas. *Ear Nose Throat J* **88**(10):E1–E3 (2009).
2. Olusesi, AbiodunDaud, and Emmanuel Opaluwah. "Postauricular advancement fascio-cutaneo-periosteal flap for closure of mastoid cutaneous fistula." *Otolaryngologia Polska* 68(5): 276-280 (2014).
3. Vira D, Andrews JC. Postauricular cutaneous mastoidfistula repair. *Otolaryngol Head Neck Surg* **147**(2 Suppl.):218 (2012).
4. Hassan Abshirini, Nader Saki, Soheila Nikakhlagh, Malihe Yavari. Evaluation of Prognostic Factors in Tympanoplasty. *Biosci., Biotech. Res. Asia* **12**(Spl. Edn. 1), p. 37-41 (2015).