

## Corneal Curvature Changes and Uncorrected Distance Visual Acuity after Corneal Collagen Cross-Linking for Progressive Keratoconus: A one year follow-up survey

SATTAR RAJABI<sup>1</sup>, MOHAMMAD AGHAZADEH AMIRI<sup>2</sup>, SEYYEDMEHDITABATABAEE<sup>3</sup>, AHMAD SALAMATRAD<sup>4</sup> and MOHAMMADYAVARI<sup>5</sup>

<sup>1</sup>Master of Optometry, Melli Bank Hospital, Tehran, Iran.

<sup>2</sup>OD.of Optometry, Head of Optometry Group and Faculty Member of Rehabilitation Sciences College, Shahid Beheshti University of Medical Sciences, Tehran, Iran.

<sup>3</sup>PhD specialist of Biostatistics, Faculty Member of Rehabilitation Sciences College, Shahid Beheshti University of Medical Sciences, Tehran, Iran.

<sup>4</sup>Ophthalmologist, Farabi Hospital, Tehran University of Medical Sciences, Tehran, Iran

<sup>5</sup>Ophthalmologist, Melli Bank Hospital, Tehran, Iran.

\*Corresponding author E-mail: Tabatabaee347@sbmu.ac.ir

DOI: <http://dx.doi.org/10.13005/bpj/783>

(Received: July 25, 2015; accepted: September 10, 2015)

### ABSTRACT

Corneal collagen cross-linking (CXL) is a therapeutic intervention to decrease the progression of keratoconus and reduce the need for keratoplasty. The present study aimed to efficacy of CXL on corneal curvature changes and uncorrected distance visual acuity (UDVA) through a one-year follow-up survey. This was a descriptive and analytical study conducted on 38 eyes of 27 patients aged 15-25 years who underwent CXL on progressive keratoconus. The levels of uncorrected distance visual acuity and the front and back surface curvatures of the cornea (using a sagittal pentacam map) were determined before and one year after surgery. The data were analyzed with statistical package SPSS (version 19). The UDVA, steep, flat, and mean curvatures of the anterior surface significantly improved by  $0.10 \pm 0.25$  LogMAR ( $P=0.012$ ),  $0.75 \pm 1.09$ D,  $0.79 \pm 1.23$ D, and  $0.79 \pm 1.10$  D ( $P < 0.05$ ), respectively. The Kmax ( $0.21 \pm 1.65$  ( $P=0.421$ )), and anterior surface astigmatism ( $-0.04 \pm 0.84$  ( $P=0.745$ )) of the cornea did not show significant changes, whereas back surface curvatures increased. CXL is an effective strategy to halt and reduce progression of keratoconus and can have an important role in limiting decrease of vision.

**Key words:** Corneal curvature, Progressive keratoconus, Cross-Linking, Uncorrected distance visual acuity

### INTRODUCTION

Keratoconus is a non-inflammatory, bilateral, asymmetrical, progressive, and ecstastic disease of the cornea; causing thinning of the cornea and reducing its mechanical strength due to the weakness of stromal collagen fibers. Irregular astigmatism and impairment in visual function is secondary to changes in the structure and organization of stromal collagen<sup>1, 2</sup>. In a long-term

research, the incidence of keratoconus has been reported as 20/100000 and 22.3/100000 in America<sup>3</sup> and in an area of Iran<sup>4</sup>, respectively. Progressive keratoconus may eventually lead to keratoplasty (PK, DALK). Hence, in recent years, finding a solution to stop its progression has been taken into account and in this regard, corneal collagen cross-linking (CXL) has been introduced. Wollensak et al. (2003) used cross-linking for keratoconus for the first time<sup>5</sup>. Studies have shown

that CXL can effectively improve and stop progressive keratoconus<sup>6</sup>, make better corneal rigidity<sup>7,8</sup>, enhance corneal resistance to enzymatic degeneration<sup>9</sup> and be raised as a strategy to limit vision loss and reduce the need for keratoplasty<sup>10</sup>. Radiation of uvA 365 nm and the use of riboflavin, as photo sensitizer, can create new covalent bonds between collagen molecules, fibers and microfibrils by photosensitized oxidation<sup>11</sup>. Studies on CXL safety have demonstrated that under appropriate UV irradiation endothelial damage will not occur and corneal thickness (excluding epithelium) is not less than 400 microns<sup>12-14</sup>. However, no serious side effects were reported<sup>5, 13, 15-17</sup>. According to the new practice of CXL and that it has not still been fully approved by the FDA, confirmation of its effectiveness requires further research in this field, especially in Iranian population with progressive keratoconus. Therefore, this study aims to evaluate the efficacy of CXL on corneal curvature changes and uncorrected distance visual acuity.

## MATERIALS AND METHODS

This was a descriptive and analytical study conducted on 38 eyes of 27 patients underwent CXL on progressive keratoconus. The CXL was carried out according to the following procedures: 1. Prep & drape; 2. Epithelial treatment with 20% alcohol for 20 sec; 3. Epithelium removal; 4. Riboflavin drop application 10 times in 30 min; 5. Ultraviolet exposure for 30 min + riboflavin; and 6. Use of bandage contact lens. Antibiotic and corticosteroid drops were prescribed, afterwards.

The inclusion criteria included that the patient suffers no ophthalmic and systemic disease except progressive keratoconus; no use of lens at least for 3 weeks before the operation; having corneal thickness > 400 microns of; Kmax d<sup>o</sup> 60 D; and lack of reaching corneal opacity or scarring phase of keratoconus.

The participants aged 15-25 years with progressive keratoconus underwent CXL following clinical examinations and required test on eyes in the Farabi Eye Specialty Hospital (Tehran, Iran).

Patients who had undergone CXL according to the inclusion criteria of the study were reviewed through an observational method and the patients eligible for the required examinations (20% higher than the sample size) were selected one year after the operation/surgery.

After calling back the patients, their post-surgery UDVA were determined and their corneal front and back surface topographies, including steep curvature (Ks), flat curvature (Kf), mean curvature (Kmean), maximum curvature (Kmax) and astigmatism level in both anterior and posterior surfaces of the cornea were examined using pentacam. Their CXL pre- and post-operative data were then compared and statistically analyzed.

Finally, the collected data were analyzed with statistical package SPSS (version 19). The data were represented as mean  $\pm$  standard deviation. To compare the normally distributed variables and those without normal distributions, paired t-test and Wilcoxon test were employed, respectively.

## RESULTS

The results indicated a significant improvement in uncorrected distance visual acuity (Fig. 1). ( $0.10 \pm 0.25$  Log MAR ( $P=0.012$ );

In addition, steep ( $0.75 \pm 1.09$ ;  $P<0.005$ ), flat ( $0.79 \pm 1.23$ ;  $P<0.005$ ), and mean ( $0.79 \pm 1.10$ ;  $P<0.005$ ) curvature changes of the front surface of the cornea (Figs. 2 and 3) were significant.

The maximum curvature ( $0.21 \pm 1.65$ ;  $P=0.421$ ) and anterior surface astigmatism ( $-0.04 \pm 0.84$ ;  $P=0.745$ ) showed no significant changes.

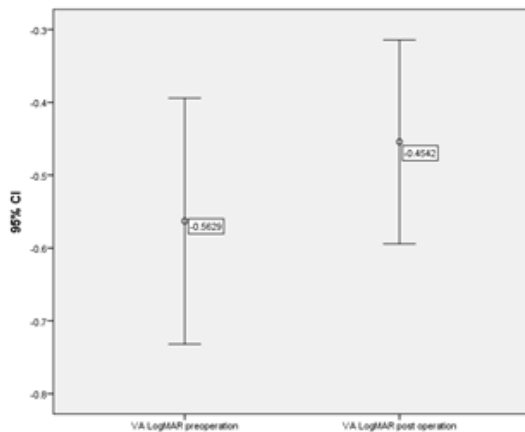
The posterior surface showed an increase in curvature (a significant change) (Fig.4) and the astigmatism level showed no significant changes ( $0.03 \pm 0.21$ ;  $P=0.303$ ).

Changes in Ks, Kf, Kmean, and Rmin of the posterior corneal surface were  $-0.12 \pm 0.18$ D,  $-0.14 \pm 0.16$  D,  $0.12 \pm 0.12$  D, and  $-0.24 \pm 0.19$  D ( $P<0.005$ ), respectively.

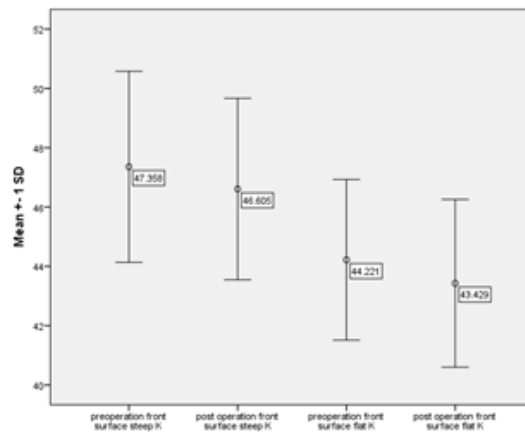
**Table 1. Distributions of mean and standard deviation statistics of the research variables and their distributions of mean differences before and 1 year after CXL surgery**

Variable	Number	Pre op. 1-year post op.		Pre op. and 1-year post op. differences	
		Mean	Mean	Mean	P-Value
UDVA	38	-0.56±0.51	-0.45±0.42	-0.10±0.25	= 0.012
FKS	38	47.35±3.22	46.60±3.06	0.75±1.09	< 0.005
FKf	38	44.22±2.70	43.42±2.82	0.79±1.23	< 0.005
FKmean	38	45.73±2.85	44.94±2.82	0.79±1.10	< 0.005
FKmax	38	50.58±3.75	50.36±4.29	0.21±1.65	= 0.421
Fast	38	3.13±1.58	3.18±1.68	-0.04±0.84	= 0.745
BKS	38	7.08±0.60	7.21±0.65	-0.12±0.18	< 0.005
BKf	38	6.37±0.46	6.51±0.51	-0.14±0.16	< 0.005
BKmean	38	6.71±0.51	6.83±0.54	-0.12±0.12	< 0.005
BRmin	38	5.08±0.52	4.84±0.55	-0.24±0.19	< 0.005
Bast	38	0.72±0.33	0.68±0.40	0.03±0.21	= 0.303

UDVA: Uncorrected distance visual acuity; F: front surface of cornea; B: back surface of cornea; K: Keratometry; s: steep; f: flat; max: maximum; min: minimum; ast: astigmatism



**Fig.1: The mean uncorrected distance visual acuity before and after CXL surgery in terms of Log MAR (P=0.05)**



**Fig. 2: Comparison of the mean steep and flat curvatures of the anterior surface of the cornea before and after CXL surgery**

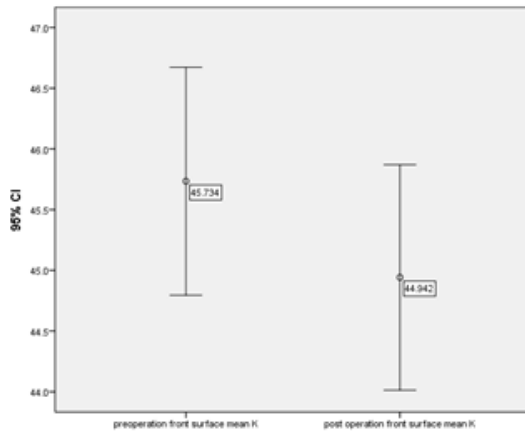
**DISCUSSION**

The corrective methods for progressive keratoconus are conventionally pursued based on the two purposes: 1. Prevention and control of its progression and 2. Improvement of sight (including using lenses, specs, Intacs, Myring, ICI, Toric Artisan, PK, and DAIK)

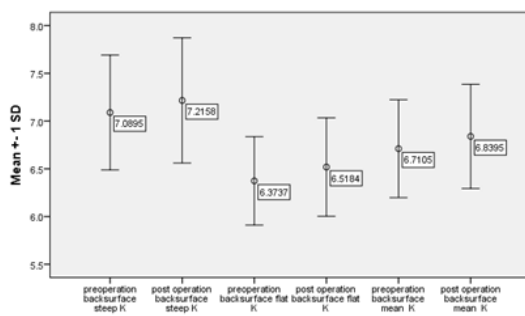
The CXL process has been considered as an effective intervention that can be effective in

controlling progressive keratoconus hence this study aimed to investigate its effectiveness by assessing corneal curvature changes and uncorrected distance visual acuity.

The use of UV length wavelength radiation and cross-linking to retrofit a material is not new as the former is used to toughen dental filling materials in dentistry and produce strong adhesives in the polymer industry, while the latter is used in orthopedics. Meanwhile, cross-linking as a natural



**Fig. 3: The mean curvature of corneal anterior surface before and after CXL surgery (P=0.05)**



**Fig. 4: Mean distributions and standard deviations of steep, flat, and mean posterior corneal surface curvatures before and after CXL surgery**

phenomenon occurs in the cornea and eye lens with aging. Corneal fibril thickness of about 4.5% increases during a person's life due to glycosylation cross-linking caused with age. Also, lens crystalline changes due to molecular weight and stiffness are caused by age-related cross-linking. The idea of using CXL for corneal stiffening was conceived in Germany in the 1990s. Researchers at the University of Dresden, Germany, found that keratoconus does not occur to or develop in diabetic patients due to glycosylation-mediated cross-linking which results in stromal resistance. Therefore, investigators tried to create the same conditions for non-diabetic persons. The ultimate results necessitated the application of riboflavin drop and 370 nm UV radiation to create cross-links between stromal collagen fibers. Therefore, the positive application of CXL for progressive

keratoconus can be promising. Furthermore, the results of this study showing significant changes in UDVA, steep, flat, and mean corneal front surface curvatures suggest that keratoconus did not only progress in the study population but also improved (Table 1).

These findings were consistent with several previous studies<sup>16,18-23</sup>. In addition, Kmax represented stability in keratoconus level. However, the difference in the values may be due to sample size, patients' ages, follow-up periods, and keratoconus intensity.

In a prospective case series study by Hashemi et al. (2013) on 40 eyes of 32 patients to evaluate CXL long-term results of patients with progressive keratoconus, mean UDVA decreased from  $0.67 \pm 0.52$  Log MAR before surgery to  $0.65 \pm 0.51$  Log MAR 5 years after surgery. The averaged Kmax and Kmean were respectively reduced by  $0.16 \pm 2.20$  D and  $0.1 \pm 1.69$  D. Additionally, astigmatism level changed from  $-3.14 \pm 2.22$  D to  $-2.49 \pm 1.71$  D. They concluded that Kmean, Kmax, UDVA, and astigmatism did not change during the 5 years after surgery, while CXL as a safe operation can stop keratoconus progression and limit the need for keratoplasty (24). Our findings support these findings where the mean UDVA varied from  $0.56 \pm 0.51$  Log MAR before surgery to  $0.45 \pm 0.42$  Log MAR after surgery, while the variations of averaged Kmax and Kmean values occurred within the ranges of  $0.21 \pm 0.65$  D and  $0.79 \pm 0.10$  D, respectively. Astigmatism change was also from  $-3.13 \pm 1.58$  D to  $-3.18 \pm 1.68$  D). This insignificant difference can be attributed to the study duration, keratoconus severity (bias caused by the inclusion Kmax value), and patients' ages. However, Hashemi et al. did not study the steep and flat curvatures of frontal surfaces alone, nor evaluated the curvatures and astigmatism level of corneal back surface.

The assessment of posterior surfaces showed that although curvatures significantly increased, the increases are not clinically significant compared to the anterior surface changes. This means that the CXL does not have a positive effect on back surface curvatures, while the trivial impact of corneal posterior compared to the anterior surface on eye refraction can be the reason for not

addressing the assessment of posterior surfaces in other studies. The findings of this study can be used in developing new therapeutic modalities as well as new high-tech approaches such as brain computer interface technique based on visual interface<sup>25</sup>.

### CONCLUSION

Progressive keratoconus may ultimately necessitate keratoplasty (PK, DAIK). Thus, considering the problems of graft rejection, high astigmatism, and long-term complications, CXL presents an important strategy to halt the progress

of keratoconus and improve it, while it can also play an effective role in limiting vision loss and reducing the need to have a corneal transplant.

### ACKNOWLEDGMENTS

The authors of this research wish to express their great appreciation to Dr. Mahmoud Jabbarvand Behrouz, the respected President of Farabi Specialty Eye Hospital, Head nurse, Optometrists and the respectful Staff of the Department of Refractive Surgery for their valuable collaboration to this study.

### REFERENCES

- Vazirani J, Basu S. Keratoconus: current perspectives. *Clinical ophthalmology* (Auckland, NZ). **7**: 2019 (2013).
- Smolek M, Beekhuis W. Collagen fibril orientation in the human corneal stroma and its implications in keratoconus. *Investigative ophthalmology & visual science*. **38**(7):1289 (1997).
- Kennedy RH, Bourne WM, Dyer JA. A 48-year clinical and epidemiologic study of keratoconus. *American journal of ophthalmology*. **101**(3):267-73 (1986).
- Ziaei H, Jafarinasab MR, Javadi MA, Karimian F, Poorsalman H, Mahdavi M, et al. Epidemiology of keratoconus in an Iranian population. *Cornea*. **31**(9):1044-7 (2012).
- Wollensak G, Spoerl E, Seiler T. Stress-strain measurements of human and porcine corneas after riboflavin-ultraviolet-A-induced cross-linking. *Journal of Cataract & Refractive Surgery*. **29**(9):1780-5 (2003).
- Kanellopoulos AJ. Comparison of sequential vs same-day simultaneous collagen cross-linking and topography-guided PRK for treatment of keratoconus. *Journal of Refractive Surgery*. **25**(9):S812 (2009).
- Seiler T, Hafezi F. Corneal cross-linking-induced stromal demarcation line. *Cornea*. **25**(9): 1057-9 (2006).
- Dupps Jr WJ, Netto MV, Herekar S, Krueger RR. Surface wave elastometry of the cornea in porcine and human donor eyes. *Journal of refractive surgery* (Thorofare, NJ: 1995). **23**(1):66 (2007).
- Spoerl E, Wollensak G, Seiler T. Increased resistance of crosslinked cornea against enzymatic digestion. *Current eye research*. **29**(1):35-40 (2004).
- Tan DT, Por Y-M. Current treatment options for corneal ectasia. *Current opinion in ophthalmology*. **18**(4):279-83 (2007).
- Sung HW, Chang WH, Ma CY, Lee MH. Crosslinking of biological tissues using genipin and/or carbodiimide. *Journal of Biomedical Materials Research Part A*. **64**(3):427-38 (2003).
- Ashwin PT, McDonnell PJ. Collagen cross-linkage: a comprehensive review and directions for future research. *British journal of ophthalmology*. **94**(8):965-70 (2010).
- Spoerl E, Mrochen M, Sliney D, Trokel S, Seiler T. Safety of UVA-riboflavin cross-linking of the cornea. *Cornea*. **26**(4): 385-9 (2007).
- Wollensak G, Spoerl E, Reber F, Seiler T. Keratocyte cytotoxicity of riboflavin/UVA-treatment in vitro. *Eye*. **18**(7):718-22 (2004).
- Greenstein SA, Fry KL, Bhatt J, Hersh PS. Natural history of corneal haze after collagen crosslinking for keratoconus and corneal ectasia: Scheimpflug and biomicroscopic analysis. *Journal of Cataract & Refractive*

- Surgery*. **36**(12):2105-14 (2010).
16. Greenstein SA, Shah VP, Fry KL, Hersh PS. Corneal thickness changes after corneal collagen crosslinking for keratoconus and corneal ectasia: one-year results. *Journal of Cataract & Refractive Surgery*. **37**(4): 691-700 (2011).
  17. Koller T, Mrochen M, Seiler T. Complication and failure rates after corneal crosslinking. *Journal of Cataract & Refractive Surgery*. **35**(8):1358-62 (2009).
  18. Legare ME, Iovieno A, Yeung SN, Kim P, Lichtinger A, Hollands S, et al. Corneal collagen cross-linking using riboflavin and ultraviolet A for the treatment of mild to moderate keratoconus: 2-year follow-up. *Canadian Journal of Ophthalmology/ Journal Canadien d'Ophthalmologie*. **48**(1):63-8 (2013).
  19. Kránitz K, Sándor GL, Knorz MC, János Németh MD D, Zoltán Zsolt Nagy MD D. Corneal changes in progressive keratoconus after cross-linking assessed by Scheimpflug camera. *Journal of Refractive Surgery*. **28**(9):645 (2012).
  20. Dahl BJ, Spotts E, Truong JQ. Corneal collagen cross-linking: an introduction and literature review. *Optometry-Journal of the American Optometric Association*. **83**(1): 33-42 (2012).
  21. Henriquez MA, Izquierdo Jr L, Bernilla C, Zakrzewski PA, Mannis M. Riboflavin/Ultraviolet A corneal collagen cross-linking for the treatment of keratoconus: visual outcomes and Scheimpflug analysis. *Cornea*. **30**(3):281-6 (2011).
  22. Kampik D, Koch M, Kampik K, Geerling G. [Corneal riboflavin/UV-A collagen cross-linking (CXL) in keratoconus: two-year results]. *Klinische Monatsblätter für Augenheilkunde*. **228**(6):525-30 (2011).
  23. Toprak I, Yildirim C. Effects of corneal collagen crosslinking on corneal topographic indices in patients with keratoconus. *Eye & contact lens*. **39**(6):385-7 (2013).
  24. Hashemi H, Seyedian MA, Miraftab M, Fotouhi A, Asgari S. Corneal collagen cross-linking with riboflavin and ultraviolet A irradiation for keratoconus: long-term results. *Ophthalmology*. **120**(8):1515-20 (2013).
  25. ALI Y, Abdolhossein B. Brain Computer Interface: Principles, Recent Advances and Clinical Challenges. *Orient J Comp Sci & Technol*. **7**(3):425-42 (2014).