

The Outcome of Endoscopic Surgery on Patients with Sinonasal Inverted Papilloma: A 10 Year Experience

SOHEILA NIKAKHLAGH¹, SANATAIEBI², LEILA SISTANI KARAMPUR²,
GHASEM NEISI³ and NADER SAKI^{1*}

¹Head and Neck Surgery, Hearing & Speech Research Center,
Ahvaz Jundishapur University of Medical Sciences, Ahvaz, Iran

²Hearing & Speech Research Center, Ahvaz Jundishapur University of Medical Sciences, Ahvaz, Iran

³Resident of Radiology, Ahvaz Jundishapur University of Medical Sciences, Ahvaz, Iran

*Corresponding author E-mail: Ahvaz.ent@gmail.com, Saki-n@ajums.ac.ir

DOI: <http://dx.doi.org/10.13005/bpj/778>

(Received: July 25, 2015; accepted: September 10, 2015)

ABSTRACT

Inverted papillomas comprises 0.5-4% of benign epithelial nasal tumors that arise primarily from the lateral nasal wall. The main characteristic is its tendency to recur and the risk of malignant transformation. The present study aims to analyze and report the findings of our team in the treatment of these lesions, especially through the endoscopic approach and the outcomes of the patients. This is a retrospective study describing 38 patients who underwent endoscopic excision or open surgery from March 2001 to March 2012. The patients were studied by age, sex, origin of lesion, presenting symptoms, radiological studies, clinical staging, method of treatment, follow up, surgical outcome, tumor recurrence and associated malignancy. The mean follow-up was 48 months. There were 30 men and 8 women with the mean age of 49.76 years ranging 18 to 78 years old. The most common clinical symptoms were unilateral nasal obstruction (94.7 %) and rhinorrhea (36.84 %). Disease recurrence rate was 5.3 %. Endonasal endoscopic resection was performed in 32 patients (84.2%), combined approaches were used for 5 patients (13.2%) and external approach only was done in one patient. The most common involvement location was the maxillary sinus (89 %). The ethmoid sinus and the lateral nasal wall were involved in 68% and 55.2% of the cases, respectively. Malignant transformation was observed in 2 patients (5.3 %). Long-term follow up of inverted papilloma is necessary for early detection of recurrence and to allow for surgical salvage. Surgeon's experience plays a crucial role in the selection of an appropriate method.

Key words: inverted papilloma, endoscopic surgery, open surgery, outcome

INTRODUCTION

Inverted papilloma is a benign sinonasal epithelial neoplasm which involves the lateral nasal wall. It comprises 0.5 – 4 % of primary nasal neoplasms, its peak age is the 5th or 6th decade of patients' life and involves men more than women¹. Clinical symptoms depend on the involvement location but the most common symptom is unilateral and progressive nasal obstruction. Other symptoms usually include unilateral sinonasal discharge but bilateral sinonasal involvement is reported in 1 – 9 % of the cases^{2, 3, 4}. A pink, polypoid, smooth or lobulated papillary mass seen in the lateral nasal

wall above the inferior turbinate in the nasal cavity during examination is indicative of inverted papilloma that can be differentiated from antrochoanal polyp or other neoplastic lesions⁵. Lateral rhinotomy and medial maxillectomy were selected as surgery methods in the past for the treatment of inverted papilloma. Endoscopic surgery is another method which was seriously proposed during the last decade. Its advantages include avoiding external incisions, maintaining the normal physiological function of the mucociliary system and the possibility of regular endoscopic examinations during post-surgery follow-ups⁶. Surgeons' views on the priority of surgical methods

are different. Several studies have indicated that the recurrence rate of endoscopic surgery is 3 – 17 % which is less than the recurrence rate of external surgery (7). The highest neoplasm recurrence rate is early recurrence at its primary location and its most important cause is incomplete removal of the neoplasm. This is why some surgeons prefer the external rhinotomy method over the endoscopic method. Therefore, the present study investigates the results and outcome of endoscopic surgery in patients with inverted papilloma administered in Imam Khomeini and Apadana Hospitals (Ahvaz, Iran) between 2001 and 2012.

MATERIALS AND METHODS

This retrospective study was conducted on 38 patients. Demographic information and medical records of the patients from 21st March 2001 to 19th March 2012 along with their pathology results were collected and were pursued for recurrence using sinonasal endoscopy and computer imaging of the sinuses. Their demographic information including age at diagnosis, gender, as well as their symptoms, location of neoplasm after diagnosis, surgery type (Endoscopic surgery, lateral rhinotomy and Caldwell-Luc surgery) were extracted. They were called and invited for a revisit and endoscopy to be checked for the recurrence of symptoms. Descriptive statistics and chi-square test were used for providing frequency tables and indices and comparing recurrence rates, respectively.

RESULTS

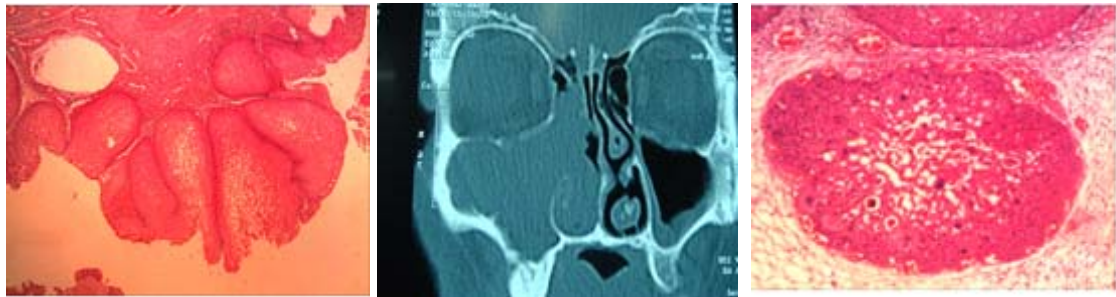Among 38 patients in the study, 30 were male (78.9 %) and 8 were female (21.1 %). The male – female ratio was 3.75:1. The mean age of the patients was 49.76 years with the age range of 18–78 years old at the time of symptoms diagnosis (Figure 2). The most common symptom was unilateral nasal obstruction (94.7%). The other symptoms included nasal discharge and postnasal drip (36.84 %), headache (13.15 %), nasal bleeding and loss of the sense of smell (the prevalence of 10.5 % for each) and voice change (2.6 %).

The sinonasal involvement was mostly unilateral. In 42.1 %, 47.4 % and 10.5 % of the

cases involvement was at the right and left and bilateral, respectively. The most common involvement location was the nasal cavity (89%), The maxillary sinus (68 %), ethmoid sinus (55.2 %), the frontal sinus(26.3%), the sphenoid sinus (23.6 %) and nasopharynx (15.87%) were the most common after the maxillary sinus. According to the Krouse classification, 7.89 %, 39.47 %, 26.31 % and 26.31 % of patients were in T₁, T₂, T₃ and T₄ classes, respectively at diagnosis. Moreover, 32 (84.2%), 5(13.2%) and 1 patients underwent endoscopic surgery, endoscopic with Caldwell-Luc surgery and lateral rhinotomy surgery, respectively. Among 38 studied patients, 6 (15.8%) underwent surgery after early diagnosis of polyposis during endoscopic examination and imaging whose side was determined in the pathological diagnosis of sinonasal inverted papilloma.

During follow-up, two patients with squamous carcinoma (5.3 %), were observed that one case was metachronous and one synchronous with the diagnosis of inverted papilloma. This patient was a 52-year-old man who had visited with nasal obstruction symptoms and nasal mass at the right. His involved sinuses were maxillary, ethmoid, frontal and sphenoid sinuses. Erosion of lamina papyracea was observed in this patient during an endoscopy surgery. He undergone endoscopy surgery and severe localized dysplasia (in situ carcinoma) was reported in his pathology (fig 1). After 36 months of follow up, no evidence of recurrence was observed in the patient . He was diagnosed with synchronous squamous carcinoma along with sinonasal inverted papilloma. The second patient was a 73-year-old man who underwent surgery with nasal obstruction. Bleeding from the right nasal cavity and sinonasal inverted papilloma were reported in his pathology. eightmonths after the surgery, symptoms recurred at the the same side. After endoscopy surgery and histopathological examination of the sample, the diagnosis of inverted papilloma along with well-differentiated squamous carcinoma was confirmed,the patient was underwent open surgery.

We had recurrence of two cases and isolated frontal sinus involvement was observed in one case. The patient had nasal obstruction and discharge with swelling of the left upper eyelid. The



Pathology of inverted papilloma Right side inverted papilloma Carcinoma insitue in inverted papilloma

Fig. 1: Radiologic & pathologic pattern of inverted papilloma

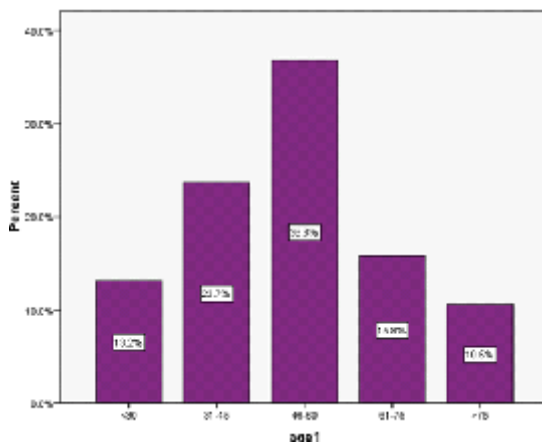


Fig. 2: Distribution of age of the patients

involvement of the frontal sinus with expansion into orbit and chronic polyposis was observed and the patient underwent surgery with the diagnosis of frontal sinus mucocele with expansion to the left orbit. Periorbital abscess, polyposis, chronic sinusitis and sinonasal inverted papilloma was reported in his pathology. This patient had a history of 3 surgeries due to polyposis and inverted papilloma was not reported in any of pathology results..

. There was no significant relationship between recurrence rate and patient age and gender based on Fisher's exact statistical test (p: 0.999). Recurrence rate was 12.5 % and 16.7 % in women and men, respectively.

DISCUSSION

Inverted papilloma is a type of sinonasal neoplasm which can occur at any age. However, the majority of patients are affected during the 5th

and 6th decade of their life. This neoplasm is more common among men. Its main characteristic is its tendency to recur and its remodeling and bone destruction ability. Although it is primarily benign, its malignant transformation is well-recognized⁸. Clinical symptoms of inverted papilloma are different depending on the extent of involvement of surrounding structures and the presence of secondary pathology. Unilateral nasal obstruction has been the most common clinical symptom in most studies.

In the past, choice of treatment for patients with sinonasal inverted papilloma was open surgery, but Nowadays, most articles support the endoscopic method as the selected method for the treatment of these patients⁹. The indication of endoscopic surgery is more widespread today and larger neoplasms can be successfully operated with this technique. External surgery methods are conducted on certain patients in combination with endoscopy in recent years¹⁰. In today's world in which surgery and hospitalization duration are two important conditions in surgical planning, endoscopic medial maxillectomy is very useful¹¹⁻¹³. Recurrence rate in external surgery methods for sinonasal inverted papilloma varies from 0 – 36 % while this rate is 0 – 25 % for endoscopic surgery methods^{8, 14}.

It is important that endoscopic surgery of neoplasms depends on the technique and is associated with potential complications. In order to ensure low recurrence rate and avoid complications, endoscopic resection of the neoplasm should be done by skilled and experienced surgeons using endoscopic sinus surgery techniques¹¹.

Moreover, the role of endoscopy is important in patient pursue. Careful observation of sinonasal cavity after surgery using endoscope results in early diagnosis of the disease and its recurrence^{11,15}. Furthermore, long-term examination is recommended since it can recur after years. Recurrent inverted papilloma is associated with the risk of squamous carcinoma and its rate is reported to be 2 – 53%. With respect to the possibility of secondary malignant transformation, long-term follow up of patients with nasal endoscopic methods and if required, CT scan and MRI is necessary^{15,16}. Imaging plays an important role in patient evaluation. It determines the extension of the neoplasm and bone erosion or invasion of surrounding structures such as skull base and orbit. These changes can predict associated malignancy and change the type of treatment. Although CT scan can determine the method of inverted papilloma surgery, MRI can reveal neoplasm spread more accurately by differentiating it from remaining discharge and associated sinusitis¹².

The majority of this study's patients were male (78.9 %) which is consistent with the majority of studies^{9,12,13}. Patients ranged 18 – 78 years old and they were 49.76 years old on average when symptoms were diagnosed which is consistent with other studies^{8,9,12}. The male – female ratio was 3.75:1 in this study. In a study by De susa *et al.*, this ratio is reported 1:1¹¹ which is inconsistent with the present study. Moreover, in a study by Baradaran far *et al.* in Yazd, male – female ratio is reportedly 11:1¹² which is inconsistent with the present study. The most common clinical symptom in this study was unilateral nasal obstruction (94.7 %) which is consistent with the majority of studies^{9,11,12,13}. The involvement location in this study was mostly unilateral which was more common on the left. In 10.5 % of patients, the involvement was bilateral which is inconsistent with the results of a study by Bhandary *et al.*,¹³. The present study is consistent with a study by De susa *et al.* in which 11.5 % of patients suffered from bilateral sinonasal involvement but the most common involved location was at the right¹¹. In the study by Baradaranfar , involvement was more common on the left and 12.5 % of patients had bilateral sinonasal involvement¹². The most common involved sinus in this study was the maxillary sinus. This issue has been studied in

other studies too^{10,11}. In a study by P. Diaz Molina, the most common involved sinus was the ethmoid sinus¹⁰. Other involved sinuses in this study include ethmoid, frontal and sphenoid sinuses in the order of their prevalence. This result is rather inconsistent with the one by De Susa in which the least common involved sinus was the frontal sinus¹¹.

Recurrence rate during this study was 5.3 % (2 patients) but no recurrence was observed during some studies¹³. This result is inconsistent with the one by the present study. In some studies, recurrence rate was reportedly 7.1 %^{10,12}. This rate was higher in some studies at about 25 %¹¹ which is inconsistent with the present study. Two cases of malignancy associated with inverted papilloma were observed during this study. Once case was in situ synchronous carcinoma and the other one was metachronous squamous carcinoma which occurred 8 months after the primary inverted papilloma diagnosis. No evidence of symptoms was observed during the study 36 and 19 months after the diagnosis of carcinoma. In a study by Bhandary *et al.*, 10.7 % of malignancy was observed with inverted papilloma and all 3 cases were squamous carcinoma¹² which was consistent with the present study.

In another study by Kim *et al.*, malignancy rate with inverted papilloma is reportedly 7 %. These patients did not have a significant age difference at diagnosis with other patients with inverted papilloma in that group. One of these malignancies was transitional carcinoma and other were squamous carcinoma, most of which were reported to be synchronous (9). In another study by P. Diaz Molina, 16 % of patients suffered malignancy along with inverted papilloma. Most of the cases were squamous cell carcinoma and 2 were transitional carcinoma most of which were synchronous¹⁰.

CONCLUSION

Today, endoscopic approaches tend to be the choice for treatment of the majority of inverted papillomas. The close follow up of the patient for a long period of time is necessary for early detection of recurrence and to allow for surgical salvage. Surgeon's experience is a determining factor when choosing the type of surgery for these cases.

ACKNOWLEDGEMENTS

The authors would like to thank the research deputy for their valuable cooperation. This paper is a part of the medical doctor thesis (Ref-No. 597) that has been financially supported by Ahvaz Jundishapur University of Medical Sciences. .

Authors' Contributions

All authors had equal role in design, work, statistical analysis and manuscript writing.

Conflict of Interest

The authors have no conflict of interests.

REFERENCES

1. Jeffrey D. Suh, MD; Alexander G. Chiu, MD. What Are the Surveillance Recommendations Following Resection of Sinonasal *Inverted Papilloma*? *Laryngoscope*. **0**(0) :1-2 (2014).
2. Oikawa K, Furuta Y, Nakamaru Y, Oridate N, Fukuda S. Preoperative staging and surgical approaches for sinonasal inverted papilloma. *Ann Otol Rhinol Laryngol*. **116**(9):674-80 (2007)
3. Gu FM, Zhang LS. Clinical Outcomes of Endoscopic and Open Resection of Recurrent Sinonasal Inverted Papilloma. *J Craniofac Surg*. (2014)
4. Wormald PJ, Ooi E, van Hasselt CA, Nair S. Endoscopic removal of sinonasal inverted papilloma including endoscopic medial maxillectomy. *Laryngoscope*. **113**(5): 867-73 (2003).
5. Nikakhlagh S, Rahim F, Saki N, Mohammadi H , Yavari M. Antrochoanal polyps: Report of 94 Cases and Review the Literature. *Nigerian Journal of Medicine*. **21**(2):156-159 (2012)
6. Busquets JM, Hwang PH. Endoscopic resection of sinonasal inverted papilloma: a meta-analysis. *Otolaryngol Head Neck Surg*. **134**: 476-482 (2006)
7. Han JK, Smith TL, Loerhl T. An evolution in the management of sinonasal inverting papilloma. *Laryngoscope*. **111**: 1395-400 (2001).
8. Roh HJ, Procop GW, Batra PS. Inflammation and the pathogenesis of inverted papilloma. *Am J Rhinol*. **18**: 65-74 (2004).
9. Kim K, Kim D, Koo Y. Sinonasal carcinoma associated with inverted papilloma :a report of 16 cases. *Journal of cranio-maxillo-facial surgery*. 1 (2011).
10. Juan P, Díaz M, José L, Llorente P, Juan P, Rodrigo T, Cesar AM, Sergio OA, Carlos SN. Inverted sinonasal papillomas. Review of 61 cases. *Acta Otorrinolaringol Esp*. **60**(6): 402-408 (2009).
11. De Sousa A, Vicenti A, Fillo S. Ana Maria AS, Alcioni BV, José SF, Michel BC. Retrospective analysis of 26 cases of inverted nasal papillomas. *Barz J Otorhinolaryngol*. **78** (1): 26-30 (2012).
12. Baradaranfar MH, Dabirmoghadam P. Trans nasal endoscopic approach for sinonasal Inverted papilloma. *Medical journal of the Islamic republic of Iran* **18**(2):127-130 (2004).
13. Bhandary S, Sinagh RK, Shrestha S. sinonasal Inverted papilloma in Eastern part of Nepal. *Kathmandu university medical journal* **4**: 431-435 (2006).
14. Schlosser RJ, Mason JC, Gross CW. Aggressive endoscopic resection of inverted papilloma: an update. *Otolaryngol Head Neck Surg*. 125-49-53 (2001).
15. Sautter NB, Cannady SB, Citardi MJ. Comparison of open versus endoscopic resection of inverted papilloma. *Am J Rhinol*. **21**: 320-323 (2007).
16. Von Buchwald C, Bradley PJ. Risk of malignancy in inverted papilloma of the nose and paranasal sinuses. *Curr Opin Otolaryngol Head Neck Surg*. **15**(2): 95-8 (2007).