

## Accuracy of Three Different Electronic Apex Locators - A Pilot Study

J. PRABHAKAR<sup>1</sup>, ALAGARSAMY VENKATESH<sup>2</sup> and GOLD PEARLIN MARY<sup>2</sup>

<sup>1</sup>Department of Conservative Dentistry and Endodontics,  
Tagore Dental College and Hospital, Chennai, India

<sup>2</sup>Department of Conservative Dentistry, Sree Balaji Dental College and Hospital,  
Bharath University, Pallikaranai, Chennai - 600100, India.

\*Corresponding author E-mail: drjprabhakar@tagoredch.in

DOI: <http://dx.doi.org/10.13005/bpj/700>

(Received: August 15, 2015; accepted: September 20, 2015)

### ABSTRACT

Accurate working length determination is a prerequisite for successful root canal treatment, reducing the chance of insufficient cleaning of the canal or of damaging the periapical tissues from over instrumentation. The use of an electronic apex locator has improved the accuracy of the working length measurement in clinical endodontics. The purpose of this in-vivo study was to compare the accuracy of three different Electronic Apex Locator (EALs). Twelve human mandibular premolar to be extracted for orthodontic treatment were selected. Teeth were divided into three groups Group 1 (n = 4) (IPex, NSK NAKANISHIINC, Tochigi, Japan) Group 2 (n = 4) (Mini Apex Locator, Sybron Endo, Glendora, CA, USA) Group 3 (n = 4) (IROOT S, S-Denti, Korea). After determining the working length the No 10 Kfile was cut at the reference point and sealed in position using Glass Ionomer cement. Tooth is extracted and apical 3- 5mm is exposed and photographed using SLR digital camera. The distance between file tip and minor apical diameter were measured using a calibrated measurement software. (Adobe .version 9). Raw data of 12 samples were recorded and inference was made. Within the limitation of this pilot study we are able to comment that all the Electronic Apex Locators evaluated in this study performed to the recommended accuracy. Further study is important to statistically analyze above mentioned comment.

**Key words:** Electronic Apex Locator, EAL, Working length

### INTRODUCTION

Accurate working length determination is a prerequisite for successful root canal treatment, reducing the chance of insufficient cleaning of the canal or of damaging the periapical tissues from over instrumentation<sup>1,2,3</sup>. Among clinicians, it is generally accepted that working length extends from the coronal portion of the root canal to the apical constriction. Various anatomic studies have determined the apical constriction to fall 0.5 to 1.0 mm from the apical opening of the tooth, or major foramen<sup>4,5</sup>.

Traditional methods for establishing working length include the use of radiography<sup>6</sup>, anatomical averages and knowledge of anatomy<sup>5,7</sup>, tactile sensation<sup>8,9</sup> and moisture on a paper point<sup>10</sup>. All of these methods have limitations<sup>11,12,6</sup>. Radiographs are subjected to distortion and magnification and are technique sensitive in both their exposure and interpretation<sup>6</sup>. Furthermore, a radiograph provides a two-dimensional image of a three-dimensional structure which lacks of a real representation<sup>13</sup>. Even amongst experienced clinicians the use of anatomical averages, knowledge of anatomy and tactile sensation has been shown unreliable and subjected to marked

intra-subject differences<sup>8, 9</sup>. Therefore, these methods for root canal measurement do not allow precise localization of apical constriction and do not guarantee that instrumentation beyond the apical foramen will be avoided<sup>14, 15</sup>.

The use of an electronic apex locator has improved the accuracy of the working length measurement in clinical endodontics<sup>13,16,15</sup>. Several *in vivo* and *ex vivo* studies have been conducted on various commercially available EALs to determine their accuracy and consistency<sup>17-20</sup>. These studies reported varying percentage of accuracy of the recent generation of EALs. The purpose of this *in-vivo* study was to compare the accuracy of three different Electronic Apex Locator (EALs).

**MATERIALS AND METHODS**

This study was approved by the ethical committee of Tagore dental college and hospital, Chennai. Patients were explained about the procedure and importance of their cooperation in the final outcome of this research study. Patients were provided with Informed Consent form in both English and Patient’s Mother tongue.

Twelve human mandibular premolar to be extracted for orthodontic treatment were selected. Patients were selected in the age group- 18-25 years. The selection criteria included tooth with fully formed apices and with no caries, no coronal restorations and no signs of resorption or cracks were chosen. The teeth were radiographed and a single root, Presence of single ,straight canal without calcification was confirmed. Teeth were divided into three groups:

- Group 1 (n = 4) (IPEX, NSK NAKANISHIINC, Tochigi, Japan)
- Group 2 ( n =4) (MINI APEX LOCATOR Sybron Endo, Glendora,CA, USA)
- Group 3 ( n=4)(IROOT S,S-Denti,Korea).

The teeth were isolated with rubber dam after anesthesia. Standard access cavity was prepared and the pulp chamber was irrigated with 3 % sodium hypochlorite. The occlusal surface of the tooth was made flat to achieve a standard reference point. After locating the canal orifice, the coronal part of the canal was enlarged with #2 to

#4 Gates-Glidden drills (Mani, Tochigi, Japan).The pulp tissues from the canal was removed with S1 Pro Taper using Anthogyr rotary hand piece upto 3 mm short of radiographic length of the tooth.

Respective EAL is used to determine the working length using No 10 K file to the assigned groups and values were recorded. After that No 10 K File is placed in the canal and cut at the coronal reference point. Then the file was sealed coronally in position using Glass ionomer cement .Tooth is extracted , cleaned and stored in distilled water.

The apical 3–5 mm of the roots were carefully removed using a diamond blade and a scalpel until the instrument and the canal walls were visible. This was performed under a light, paying attention to the anatomical canal characteristics. The exposed apical portion of the apex is photographed using SLR digital camera (Nikkon, Japan). Pictures were loaded to a computer and analyzed with a calibrated measurement software.(Adobe .version 9). The distance between file tip and minor apical diameter were measured. (Fig 1).Minor apical diameter is determined by reducing 0.5mm from anatomical apex .

**RESULTS AND DISCUSSION**

The results are presented in the table 1. The use of electronic devices to determine working length has gained increasing popularity in recent years. Custer first introduced the concept in 1916, which was later revisited by Suzuki in 1942 when

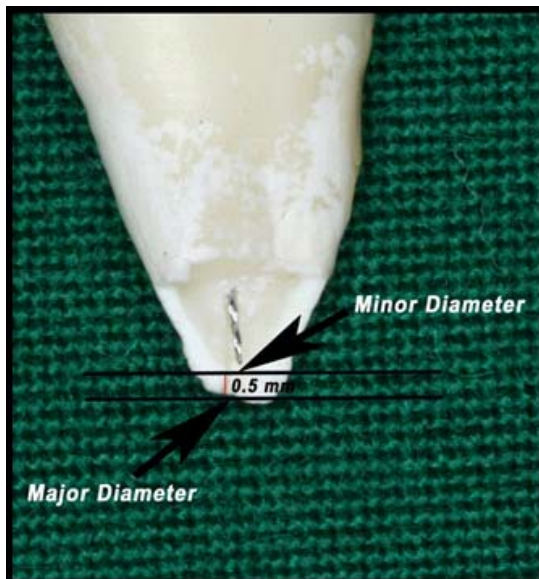
**Table 1: Raw data of 12 samples with measurements between the minor diameter and file tip**

GROUP 1 (n==4) IPex	1.	0.14mm
	2.	0.14mm
	3.	0.16mm
	4.	0.15mm
GROUP2 (n=4) Mini Apex Locator	1.	0.21mm
	2.	0.18mm
	3.	0.22mm
	4.	0.17mm
GROUP3 (n=4) I Root	1.	0.18mm
	2.	0.17mm
	3.	0.17mm
	4.	0.20mm

he observed that a consistent electrical resistance between an instrument in a root canal and an electrode on the oral mucous membrane could be used for measuring canal length<sup>21,22</sup>. Since that discovery, several generations of EALs have been developed to refine their accuracy.

The first generation of EALs were largely resistance based and were found to both over and underestimate working length when compared to radiographs. Second generation EALs rely on impedance measurements to measure the location within a canal. These devices often have difficulty taking accurate measurements in wet canals, and require insulative sheaths over the probe to protect them from conductive fluids. Third generational devices are largely frequency-based and use multiple frequencies to determine the distance from the end of the canal. Certain third generational devices use a ratio algorithm between two electrical currents and are designed to make accurate readings regardless of fluid electrolytes being present within the canal. Recently, fourth generation devices have arrived in the market that claim to use differing frequencies to further reduce errors<sup>23</sup>. The Electronic apex locators used in this study were fourth generation devices.

Apical anatomy determines the termination of root canal instrumentation and filling.



**Fig. 1: Picture showing calibration using Adobe software**

The cemento-dentinal junction (CDJ), which is also described as the apical constriction<sup>23</sup>, is the anatomical and histological landmark where the periodontal ligament begins and the pulp ends<sup>24</sup>. The CDJ is highly irregular and can be up to 3 mm higher on one wall of the root compared with the opposite wall<sup>25</sup>. Furthermore, the CDJ cannot be identified clinically<sup>2</sup>. The ideal spot for working length determination in endodontic treatment is the apical constriction. As the mean foramen to apical constriction distance is approximately 0.5–1.0 mm for all tooth types<sup>4,5,26</sup>, it was chosen in this study to determine the minor apical diameter by subtracting 0.5 mm from the anatomical apex. We have used modified Altenburger *et al* methodology<sup>27</sup> to evaluate the accuracy of electronic apex locator.

Two levels of accuracy for electronic apex locator are defined in the literature. A distance of 1.0 mm from the apical constriction is regarded as clinically acceptable<sup>28</sup>. However, the clinical tolerance of 0.5 mm to the apical constriction is regarded as being superior<sup>29</sup>. All the groups evaluated in this study shows the reading less than that of 0.5 mm (Table.1). It can be inferred that all the EALs evaluated in this preliminary study produces clinically acceptable accuracy. Although these modern devices are superior than conventional methods, the fact remains that still 100 percent accuracy yet to be achieved. Several studies reported that the accuracy of the recent generation of EALs was approximately 90 percent<sup>30-33</sup>. Thus mechanical instrumentation without irrigation cannot predictably eliminate bacteria in the canal completely. A root canal irrigant is needed to aid in the debridement of the B root canals. In this study none of the groups were the file tips found exactly at the minor apical foramen or beyond the minor apical foramen.

## CONCLUSION

Within the limitation of this pilot study we are able to comment that all the Electronic Apex Locators evaluated in this pilot study performed to the recommended accuracy. Further study is important to statistically analyze above mentioned comment.

## REFERENCES

1. Sjögren U, Hagglund B, Sundqvist G, Wing K Factors affecting the long-term results of endodontic treatment. *Journal of Endodontics* **16**: 498-504 (1990).
2. Ricucci D., Langeland K., Apical limit of root canal instrumentation and obturation, Part II: A histological study. *International Endodontic Journal* **31**: 394-409 (1998).
3. Chugal NM, Clive JM, Spangberg LS., Endodontic infection: Some biologic and treatment factors associated with outcome. *Oral Surgery, Oral Medicine, Oral Pathology, Oral Radiology and Endodontics* **96**: 81-90 (2003).
4. Kuttler Y. Microscopic investigation of root apexes. *Journal of the American Dental Association* **50**: 544-52 (1955).
5. Green D. A stereomicroscopic study of 700 root apices of maxillary and mandibular anterior teeth. *Oral Surgery, Oral Medicine, Oral Pathology* **13**: 728-33 (1960).
6. Stein TJ, Corcoran JF., Radiographic 'working length' revisited. *Oral Surgery, Oral Medicine and Oral Pathology* **74**: 796-800 (1992).
7. Burch JG, Hulén S., The relationship of the apical foramen to the anatomic apex of the tooth root. *Oral Surgery, Oral Medicine and Oral Pathology* **34**: 262-7 (1972).
8. Seidberg BH, Alibrandi BV, Fine H, Logue B Clinical investigation of measuring working lengths of root canals with an electronic device and with digital-tactile sense. *Journal of the American Dental Association* **90**: 379-87 (1975).
9. Chandler NP, Bloxham GP., Effect of gloves on tactile discrimination using an endodontic model. *International Endodontic Journal* **23**: 97-9 (1990).
10. Ruddle CJ., Cleaning and shaping root canal systems. In: Cohen S, Burns RC, eds. *Pathways of the Pulp*, 8th edn. St Louis, MO: Mosby, 231-91 (2002).
11. Tamse A, Kaffe I, Fishel D., Zygomatic arch interference with correct radiographic diagnosis in maxillary molar endodontics. *Oral Surgery, Oral Medicine and Oral Pathology* **50**: 563-6 (1980).
12. Olson AK, Goerig AC, Cavataio RE, Luciano J., The ability of the radiograph to determine the location of the apical foramen. *International Endodontic Journal* **24**: 28-35 (1991).
13. Pratten D, McDonald NJ., Comparison of radiographic and electronic working lengths. *Journal of Endodontics* **22**: 173-6 (1996).
14. ElAyouti A, Weiger R, Lost C., Frequency of overinstrumentation with an acceptable radiographic working length. *Journal of Endodontics* **27**: 49-52 (2001).
15. ElAyouti A, Weiger R, Lost C., The ability of root ZX apex locator to reduce the frequency of overestimated radiographic working length. *Journal of Endodontics* **28**: 116-9 (2002).
16. Fouad AF, Reid LC., Effect of using electronic apex locators on selected endodontic treatment parameters. *Journal of Endodontics* **26**: 364-7 (2000).
17. Fouad AF, Krell KV, McKendry DJ, Koorbusch GF, Olson RA., A clinical evaluation of five electronic root-canal length measuring instruments. *Journal of Endodontics* **16**: 446-9 (1990).
18. Mayeda DL, Simon JH, Aimar DF, Finley K In vivo measurement in vital and necrotic canals with the Endex apex locator. *Journal of Endodontics* **11**: 545-8 (1993).
19. Shabahang S, Goon WWY, Gluskin AH., An in vivo evaluation of Root ZX electronic apex locator. *Journal of Endodontics* **22**: 616-8 (1996).
20. Dunlap CA, Remeikis NA, BeGole EA, Rauschenberger CR., An in vivo evaluation of an electronic apex locator that uses the ratio method in vital and necrotic canals. *Journal of Endodontics* **24**: 48-50 (1998).
21. Custer LW. Exact methods of locating the apical foramen. *J Natl Dent Assoc* **5**: 815-9 (1916).
22. Suzuki K. Experimental study on iontophoresis. *Japanese Journal of Stomatology* **16**: 411-29 (1942).
23. Gordon MPJ and Chandler NP. Electronic

- apex locators. *International Endodontic Journal* **37**: 425-437 (2004).
24. Grove CJ., The value of the dentinocemental junction in pulp canal surgery. *Journal of Dental Research* **11**: 466-8 (1931).
  25. Gutierrez JH, Aguayo P., Apical foraminal openings in human teeth. Number and location. *Oral Surgery, Oral Medicine, Oral Pathology, Oral Radiology and Endodontics* **79**: 769–77 (1995).
  26. Dummer PMH, McGinn JH, Rees DG., The position and topography of the apical canal constriction and apical foramen. *International Endodontic Journal* **17**: 192–8 (1984).
  27. Altenburger et al Combination of apex locator and endodontic motor for length control during root canal treatment. *International Endodontic Journal*, **42**: 368–374 (2009).
  28. Tselnik M, Baumgartner JC, Marshall, JG. An evaluation of Root ZX and Elements diagnostic apex locators. *Journal of Endodontics* **31**: 507-09 (2005).
  29. Wrbas KT, Ziegler AA, Altenburger MJ, Schirrmeister JF. *In vivo* comparison of working length determination with two electronic apex locators. *International Endodontic Journal* **40**: 133-138 (2006).
  30. Fouad AF, Rivera EM, Krell KV., Accuracy of the Endex with variations in canal irrigants and foramen size. *Journal of Endodontics* **19**: 63–7 (1993) .
  31. Frank AL, Torabinejad M., An in vivo evaluation of Endex electronic apex locator. *Journal of Endodontics* **19**: 177–9 (1993).
  32. Weiger R, John C, Geigle H, Lost C., An in vitro comparison of two modern apex locators. *Journal of Endodontics* **25**: 765–8 (1999) .
  33. Welk AR, Baumgartner JC, Marshall JG., An in vivo comparison of two frequency-based electronic apex locators. *Journal of Endodontics* **29**: 497–500 (2003).