

Pseudoanodontia - Orthodontics to the Rescue?

A. ARIFYEZDANI

Department of Orthodontics and Dentofacial Orthopaedics, Bharath University,
Sree Balaji Dental College and Hospital, Narayanapuram, Pallikaranai, Chennai - 600100, India.

*Corresponding author E-mail: arifyezdani@yahoo.com

DOI: <http://dx.doi.org/10.13005/bpj/698>

(Received: August 15, 2015; accepted: September 20, 2015)

ABSTRACT

This case report highlights the treatment of a skeletal Class II malocclusion with pseudoanodontia that indicated clinical but not radiographic absence of teeth. A 21-year-old female patient presented with a skeletal Class II malocclusion with an orthognathic maxilla and a retrognathic mandible, with Angle's Class I malocclusion with rotated maxillary and mandibular anteriors with fourteen impacted maxillary and mandibular teeth. Impacted mandibular right and left third molars were advised to be removed surgically. Maxillary right first premolar and left second premolar and mandibular right and left lateral incisors were surgically removed. Surgical exposure of the remaining multiple impacted teeth was done. Pre adjusted edgewise appliance, Roth's prescription .018 inch slot was strapped up. Orthodontic extrusion of the impacted teeth was advocated. The seven impacted teeth were effectively treated with orthodontic traction. This improved the patients' esthetics, speech and self-esteem considerably.

Key words: multiple impacted teeth, surgical exposure, orthodontic traction.

INTRODUCTION

In clinical practice, delayed tooth eruption (DTE) is the most commonly encountered deviation from normal eruption time. It has been reported that DTE might be the primary or sole manifestation of local or systemic pathology¹. Various genetic disorders and syndromes have DTE as a common feature. The delay in eruption was found to be greatest in children younger than 6 years but not much in those who were above 9 years^{2,3}. However, adults too have exhibited delayed tooth eruption. Individual, sexual, racial and ethnic factors can influence eruption and determine standards of normal eruption⁴⁻⁶. DTE can significantly impact the patient's health care and can affect diagnosis, treatment planning and timing of treatment for the orthodontic patient.

Becker⁷ suggested that root development alone should be the basis for defining the expected

time of eruption for different teeth. Nonankylosed teeth too fail to erupt fully or partially because of malfunction of the eruption mechanism that occurs even though there seems to be no barrier to eruption and this phenomenon is considered to be due to a primary defect in the eruptive process⁸⁻¹⁰. Orthodontic traction of impacted teeth has been a standard and an accepted procedure in orthodontics. The following is a case report that attempts to use orthodontic traction to successfully erupt all the impacted teeth into the oral cavity.

Case report

Diagnosis and etiology

A 21-year-old female patient presented with pseudoanodontia with crowded and rotated maxillary and mandibular incisors with speech difficulty.

Extraoral assessment

The patient had a mesoprosopic face,

convex profile, posterior divergence, incompetent lips, with no signs of temporomandibular joint dysfunction.

Intraoral assessment. Oral hygiene was poor. The maxillary arch was U-shaped with crowded and rotated maxillary incisors with impacted 13, 15, 23, 24, and 25. The mandibular arch was V-shaped with severely rotated mandibular central incisors and impacted 32, 33, 38, 42, 43, 44, and 48. Retained 63 and severely carious 16 with pronounced bulge in the alveolar mucosa in the upper right quadrant was observed. Increased overjet and deep bite was present. The maxillary and mandibular dental midlines coincided with each other and with the skeletal midlines. On left side the molar relation was Class I and the curve of Spee was increased. (Fig 1a-e, Fig 2a-b).

Radiographic assessment. The panoramic radiograph confirmed the presence of impacted 13, 15, 23, 24, 25, 32, 33, 38, 42, 43, 44, and 48, with altered alveolar bone levels. (Fig 3).

Treatment objectives

The main treatment objective was to correct the pseudoanodontia and improve the speech and smile esthetics. Greater emphasis was laid for the correction of the crowded and rotated maxillary and mandibular incisors and to attempt orthodontic traction of the multiple impacted teeth.

Treatment alternatives

The severely impacted teeth could have been surgically removed and a prosthesis been given to replace the missing teeth, but the patient was not desirous of the same. The second alternative was to surgically expose the multiple impacted teeth and apply orthodontic traction to erupt these teeth. Patient was willing to undergo the second alternative to salvage the unerupted teeth.

Treatment progress

Deeply carious 16 and retained 63 were extracted. Pre adjusted edgewise appliance, Roth's prescription .018 inch slot was strapped up prior to the surgical procedure. Flaps were raised in the maxillary and the mandibular dental arches and the severely rotated 14 which was an impediment

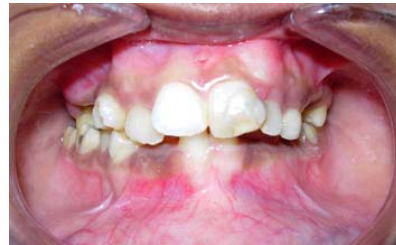

Fig. 1(a): Pre-treatment intra-oral-Frontal

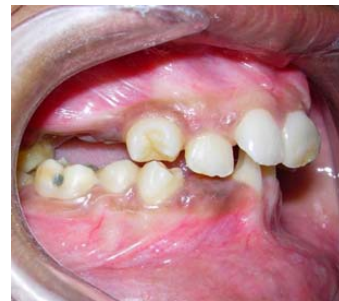

Fig. 1(b): Pre-treatment intra-oral-Right

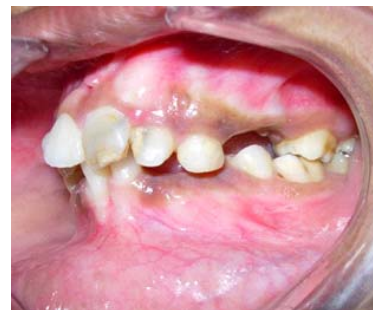

Fig. 1(c): Pre-treatment intra-oral-Left

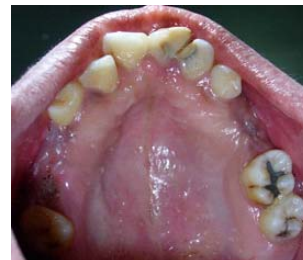

Fig. 1(d): Pre-treatment intra-oral-Upper Occlusal

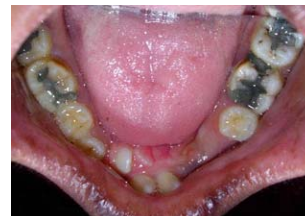

Fig. 1(e): Pre-treatment intra-oral-Lower Occlusal

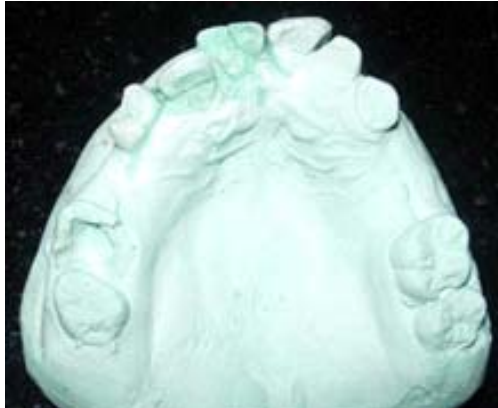


Fig. 2(a): Pre-treatment maxillary cast

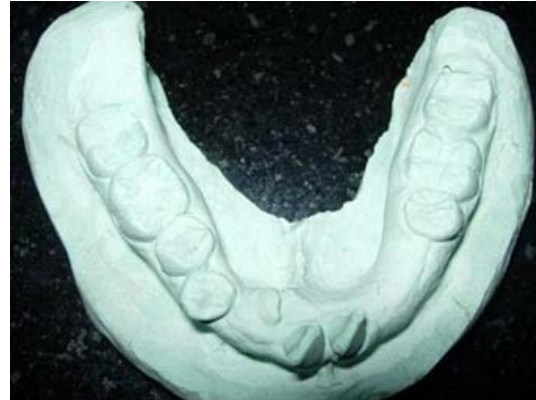

Fig. 2(b): Pre-treatment mandibular cast

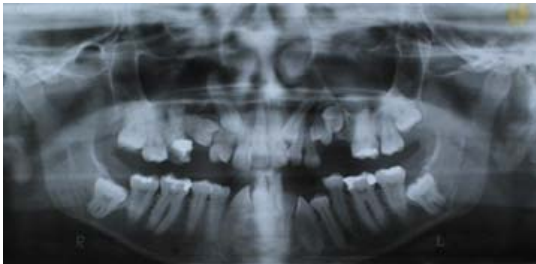

Fig 3. Pre-treatment panoramic radiograph.

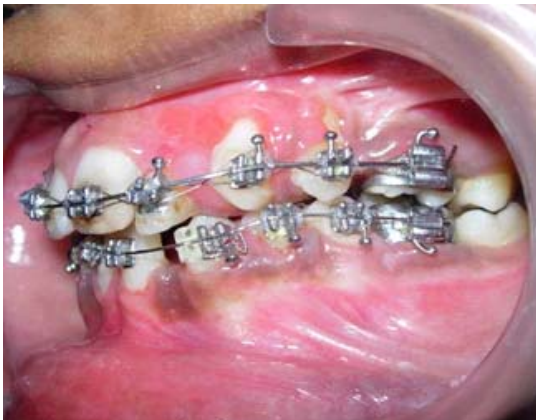

Fig 4. Surgical exposure and orthodontic traction

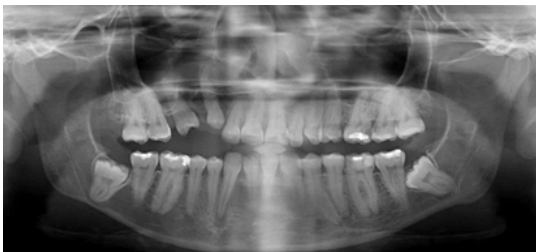

Fig. 5: Post-treatment panoramic radiograph

for the orthodontic traction of 13 and 25 which was ectopically placed was surgically removed due to poor prognosis. 32 and 42 too were surgically removed. Subsequent to maintaining a moistureless field in the vicinity of the impacted teeth, these teeth were bonded with their respective brackets with a dangling stainless steel ligature wire to assist in closed orthodontic traction. The flaps were subsequently closed back and sutured. After a week the sutures were removed and orthodontic traction was commenced with light force. (Fig 4). After successful orthodontic traction, leveling and alignment was done with 0.014 and 0.016 inch nickle titanium archwires. Space consolidation was done with 0.017 x 0.025 stainless steel archwires and final detailing and finishing with 0.019 x 0.025 stainless steel archwires.

Treatment outcome

The patient showed remarkable improvement in the correction of the multiple impacted teeth. 13, 15, 23, 24, 33, 34, and 43 were successfully erupted with orthodontic traction. After treatment, good facial harmony, balance and smile esthetics was achieved. Speech improved drastically. Normal overjet was achieved with alignment of maxillary and mandibular anteriors. The post treatment panoramic radiograph showed normal levels of alveolar bone with no root resorption (Fig 5). The post treatment lateral cephalometric radiograph was taken to gauge the treatment changes that was achieved. Endodontic treatment was done for 21 and 22 and fixed partial denture was given for 21, 22 .

DISCUSSION

Pseudoanodontia is a descriptive term that indicates clinical but not radiographic absence of teeth that should normally be present in the oral cavity for the patient's dental and chronologic age. The cause could have been retained deciduous teeth or that the deciduous teeth had shed but the permanent ones had failed to erupt.

Delayed tooth eruption is a condition where the tooth has developed more than the root length expected for eruption but remains unerupted. Gron¹¹ showed that tooth eruption begins when $\frac{3}{4}$ of its final root length is established whereas normal biologic eruption time is defined as tooth eruption that occurs when the dental root is approximately $\frac{2}{3}$ its final length. Rasmussen and Kotsaki¹² suggested using established norms for mean eruption ages calculated from population studies. By the norms suggested the case exhibited delayed tooth eruption despite the patient being 21 years of age. Various local conditions like supernumerary teeth¹³, mucosal barrier¹⁴, gingival hyperplasias¹⁵, scar tissue¹⁶, and tumors like odontomas¹⁷ cause DTE. Traumatic injuries can lead to ectopic eruption or physical displacement of the permanent germ^{18,19} or disruption in normal odontogenesis in the form of dilacerations²⁰. Ankylosis and arch-length deficiency are also etiologic factors for crowding and impactions²¹. Systemic conditions like metabolic, endocrine and genetic disorders and drugs too can cause DTE. Extremes of nutritive deprivation on calcification and eruption have been reported²². A deficiency in an essential nutrient or a high metabolic demand on the growing tissues might influence the eruptive process. Endocrine disorders²³ like hypothyroidism, hypopituitarism, hypoparathyroidism, are associated with DTE. Renal failure²⁴ and anemic hypoxia²⁵ too have been correlated with DTE. The patient was anemic as gleaned by the blood reports. The delayed onset of the presence of a gene suggested for tooth eruption might be responsible for DTE in "inherited retarded eruption"¹². This could explain the frequency of DTE

in the posterior teeth which correlates with the case reported too. Lack of appropriate inflammatory response, increased bone density and inadequate expression of some cytokines that impede resorption have been noted to be factors for DTE in some syndromes.

The patient despite exhibiting fourteen impacted teeth did not have any supernumerary teeth or odontomas. The patient deferred the extraction of impacted 38 and 48 to a later date but was willing to undergo orthodontic traction for all the other seven impacted teeth. Orthodontic traction of impacted teeth has been widely reported in literature²⁶⁻²⁸. Orthodontic traction of the multiple impacted teeth was successfully performed alongwith established orthodontic bio-mechanics. No ankylosis was encountered during the process of orthodontic traction. 13, 15, 23, 24, 33, 34, and 43 were successfully erupted with orthodontic traction with light orthodontic force and the alveolar bone was well maintained due to this procedure. On the other hand, extraction of all the impacted teeth would have greatly compromised the alveolar bone level. 18 and 28 erupted normally as space was created in the maxillary arch during orthodontic treatment. Fixed prosthesis was given in 21, 22 region to enhance esthetics. The patient was insistent on removal of the appliance a little early than the prescribed time as she was getting married and hence effective extrusion of 13 and 15 could not be adequately achieved to provide for a fixed partial prosthesis for 13,14, and 15. The patients' self-esteem, smile esthetics and speech improved dramatically.

CONCLUSION

Orthodontic traction of seven impacted teeth was successfully achieved in the case reported which in turn favourably improved the alveolar bone level and the patient was able to have a fairly good complement of teeth which undoubtedly improved her speech, mastication, occlusion and esthetics.

REFERENCES

1. Suri L, Gagari E, Vastardis H. Delayed tooth eruption: Pathogenesis, diagnosis, and treatment. A literature review. *Am J Orthod Dentofacial Orthop* 126: 432-45 (2004).
2. Seow WK, Humphrys C, Mahanonda R, Tudehope DI. Dental eruption in low birth-

- weight prematurely born children: a controlled study. *Pediatr Dent* **10**: 39-42 (1988).
3. Harila-Kaera V, Heikkinen T, Alvesalo L. The eruption of permanent incisors and first molars in prematurely born children. *Eur J Orthod* **25**: 293-9 (2003).
 4. Schour I, Massler M. The development of human dentition. *J Am Dent Assoc* **28**:1153-60 (1941).
 5. Nolla CM. The development of the human dentition. *ASDC J Dent Child* **27**:254-66 (1960).
 6. Moorrees CFA, Fanning EA, Hunt EEJ. Age variation of formation stages for ten permanent teeth. *J Dent Res* **42**:1490-502 (1963).
 7. Becker A. The orthodontic treatment of impacted teeth. London: Martin Dunitz (1998).
 8. Proffit WR, Vig KW. Primary failure of eruption: a possible cause of posterior open bite. *Am J Orthod* **80**:173-90 (1981).
 9. O'Connell AC, Torske KR. Primary failure of tooth eruption: a unique case. *Oral Surg Oral Med Oral Pathol Oral Radiol Endod* **87**:714-20 (1999).
 10. Pytlik W. Primary failure of eruption: a case report. *Int Dent J* **41**:274-8 (1991).
 11. Gron AM. Prediction of tooth emergence. *J Dent Res* **41**:573-85 (1962).
 12. Rasmussen P, Kotsaki A. Inherited retarded eruption in the permanent dentition. *J Clin Pediatr Dent* **21**: 205-11 (1997).
 13. Shafer WG., Hine MK, Levy BM. Textbook of oral pathology. Philadelphia: W.B. Saunders (1983).
 14. Goho C. Delayed eruption due to overlying fibrous connective tissue. *ASDC J Dent Child* **54**:359-60 (1987).
 15. Katz J, Guelmann M, Barak S. Hereditary gingival fibromatosis with distinct dental, skeletal and developmental abnormalities. *Pediatr Dent* **24**:253-6 (2002).
 16. Di Biase DD. Mucous membrane and delayed eruption. *Dent Pract Dent Rec* **21**:241-50 (1971).
 17. Flaitz CM, Hicks J. Delayed tooth eruption associated with an ameloblastic fibro-odontoma. *Pediatr Dent* **23**:253-4 (2001).
 18. Hawe RR. Traumatized primary teeth. *Dent Clin North Am* 391-404 (1966).
 19. Brin I, Ben-Bassat Y, Zilberman Y, Fuks A. Effect of trauma to the primary incisors on the alignment of their permanent successors in Israelis. *Community Dent Oral Epidemiol* **16**: 104-8 (1988).
 20. Andreasen JO, Andreasen FM. Textbook and colour atlas of traumatic injuries to the teeth. Copenhagen; Munksgaard (1994).
 21. Andreasen JO, Petersen JK, Laskin DM. Textbook and colour atlas of tooth impactions. St. Louis: Mosby (1997).
 22. Garn SM, Rohmann CG. Interaction of nutrition and genetics in the timing of growth. *Pediatr Clin North Am* **13**: 353-79 (1966).
 23. Shaw L, Foster TD. Size and development of the dentition in endocrine deficiency. *J Pedod* **13**:155-60 (1989).
 24. Giglio MJ, Frid A, Barcat JA, Arrizurieta E. Depressed eruption dental rate in rats with hemodynamically mediated acute renal failure. *Acta Odontol Lationoam* **8**:27-37 (1994).
 25. Giglio MJ, Sanz AM, Bozzini CE. Depressed eruption rate of the rat maxillary incisor in a drug-induced uncompensated hemolytic state model. *J Dent Res* **69**:906-8 (1990).
 26. Richard Scott Conley, Scott B. Boyd. Harry L. Legan, Christopher C. Jernigan, Craig Starling and Christopher Potts. Treatment of patient with multiple impacted teeth. *The Angle Orthodontist*. **77**:735-741 (2007).
 27. Giliana-Lun Peng, Yu-Yu, Sheng-Yang Lee. Unilateral horizontally impacted maxillary canine and first premolar treated with a double archwire technique. *The Angle Orthodontist* **76**: 502-509 (2006).
 28. Giliana Clauser Zuccati, Tiziana Doldo. Multiple bilateral impactions in an adolescent girl. *Am J Orthod Dentofacial Orthop* **137**: S163-S172 (2010).