

## Resin Infiltration Technique for Arresting white Spot Lesion: Case Report

S. RAJASEKARAN<sup>1</sup>, R. JAYAPRAKASH<sup>1</sup>, N. ARAVINDHA BABU<sup>2</sup> and K. M. K. MASTHAN<sup>2</sup>

<sup>1</sup>Department of Pedodontics and Preventive Dentistry,  
Tagore Dental College and Hospital, Chennai, India.

<sup>2</sup>Department of Oral and Maxillofacial Pathology, Sree Balaji Dental College & Hospital,  
Bharath University, Chennai-600100, India.

DOI: <http://dx.doi.org/10.13005/bpj/679>

(Received: July 25, 2015; accepted: September 10, 2015)

### ABSTRACT

Management of white spot lesion has always been an important issue in modern dentistry. Many methods have been suggested to prevent (or) slow the demineralization of enamel as soon as white spot lesion begins to appear. The following article illustrates the use of a novel approach to treat smooth surface non cavitated white spot lesions microinvasively based on infiltration of enamel caries with low viscosity light cure resin through infiltration. This treatment aims upon both the prevention of caries progression and improving esthetics by diminishing the opacity.

**Key words:** Case Report, microinvasively, Infiltration.

### INTRODUCTION

Caries is still the most prevalent chronic childhood disease and continues to affect a high percentage of adolescents, young and middle-aged adults, and seniors. Much research has proven that dental caries is not just an occasional cycle of cavitation, but a complex and infectious disease process. Addressing the caries challenge has relied on prevention and restoration, with no intermediary means to stop lesion progression. This article discusses a micro invasive technique for arresting white spot lesion<sup>1</sup>.

#### White spot lesion

White spot lesions are early signs of demineralization under the intact surface of enamel. Cause for white spot lesion is leaching out of enamel ( calcium & phosphate ions ) by organic acids produced by bacteria. Loss of unmineralized layer create porosities that changes the refractory index of usually translucent enamel<sup>2</sup>.

### Treatment modalities

#### Non invasive

- Fluoride
- CPP-ACP
- Tricalcium phosphate (TCP)
- Ion exchange resin

#### Microinvasive

- Resin infiltration

#### Invasive

- Restorations

Why the resin infiltration technique is preferred than other treatment methods ?

1. Remineralization of white spots takes longer time & inhibits the mineralization of subsurface lesions. During remineralization stains can be incorporated into the lesion leading to formation of brown spots<sup>4</sup>.
2. Application of topical fluoride arrests the lesion (hypermineralization) and prevents

- complete repair<sup>4</sup>.
3. Restoration inevitably necessitates removing certain amounts of healthy hard tissue surrounding the cavitated lesion<sup>4</sup>.

**How the resin infiltration technique works?**

Resin infiltration prevents further progression of white spots & occludes the micro porosities with in the lesion. Sealants applied to the surface that form a “cap” over incipient caries lesions,

- An analogy is how a sugar cube or sponge absorbs liquid.



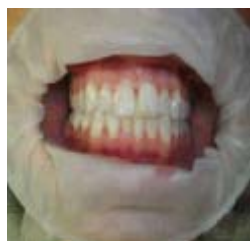**Advantages of resin infiltration technique**

- Micro invasive treatment for early demineralization
- The infiltrating resin has a high refractive index and produces a chameleon effect.
- Requires no shade matching.
- The tooth form remains unchanged
- Painless procedure use of local anesthesia is not required

**Disadvantages of resin infiltration technique**

- Cannot be used in the lesion involving dentin.
- Cannot be used in case of root caries.
- Cannot be used in cavitated lesion.

**Rubber dam is applied to achieve clean & dry working condition**

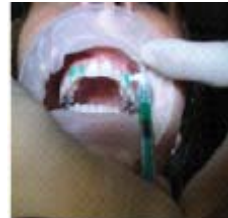

**Procedure**

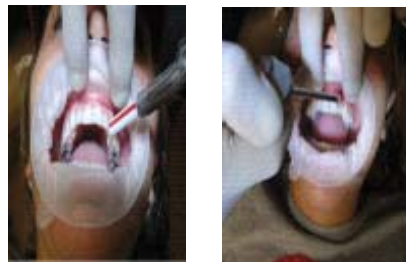**Prerequisites**

- Erosion of surface layer
- Desiccation of the lesion
- Use of special resins (infiltrates)
- Sufficient application time

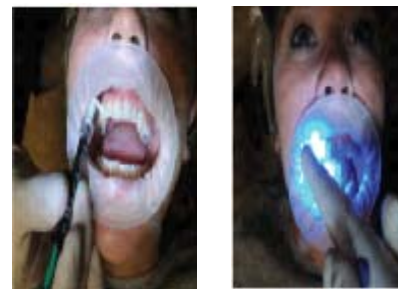**Application of 15 % HCL to etch the surface of the teeth**



**Evacuation of etch and drying**



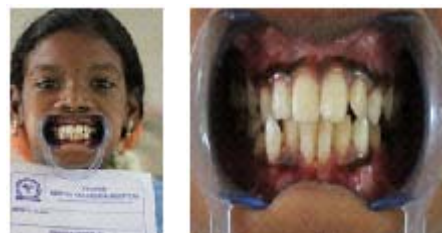**Resin infiltration and light curing**



**Case presentation**

A 12 years old girl presented with the chief complaint of whitespot in the upper left central incisor (21)

**Pre-operative photograph**



**Treatment objectives**

The treatment aim was to treat white spot lesion with non invasive resin infiltration

**Materials used**




- 15 % hydrochloric acid
- Ethanol
- DMG

**Steps in resin infiltration**

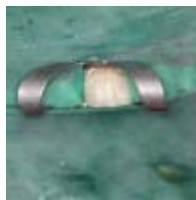**Polishing the tooth surface**

Oral prophylaxis and polishing done with prophylaxis paste

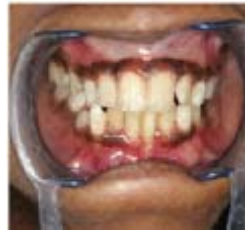**Etching**



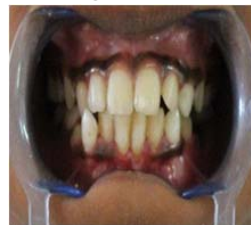**Infiltration**



**Post-operative photograph**



**Pre-operative photograph**



**CONCLUSION**

Although numerous options exist for caries prevention which mostly relies on patient cooperation & require multiple visit & application .Caries infiltration can be used to arrest lesions in one patient visit with no drilling or anesthesia.However, investigation is still needed (particularly with longer follow-ups and larger samples) as well as the development of specific and simplified protocols.

**REFERENCE**

1. *Open journal of dentistry and oral medicine* **3**(1):1-6,(2015): management of white spot lesions using resin infiltration technique: A review
2. Neerajgughani, inderk.pandit- caries infiltration of noncavitated white spot lesions: A novel approach for immediate estheticimprovement,*Contemporary clinical dentistry* **3**(2):(2012)
3. Ana Coelho, vivianamacho,A Treatment of white spot lesion by resin infiltration, *annual research & review in biology*, **4**(24)(16-31 december)
4. McDonald R E, Avery D R. Dentistry for the child and adolescent. 7th ed. pp134-7. St. Louis: Mosby Inc.,1999.
5. Gray GB, shellis p-infiltration of resin into white spot caries-like lesions of enamel: an in vitro study. *Eur j prosthodontrestor dent*; **10**:27-32 (2002).
6. Donlykj, ruiz m-In vitro demineralization inhibition of enamel caries utilizing an unfilled resin. *Clinprev dent* ; **14**: 22-24 (1992).

7. Myer-luekel H, paris S-Improved resin infiltration of natural caries lesions. *J dent res*; **87**:1112-1116 (2008)
8. Gwinnett AJ-Structure and composition of enamel. *Oper dent; suppl* **5**: 10-17 (1992).
9. Paris S, Meyer-lueckel H, kielbasa AM-Resin infiltration natural caries lesion.*j dent res*; **86**:662-666 (2007)
10. Christian h.splieth, Revolutions in pediatric dentistry.