

## Supernumerary Tooth Associated with an Mesiodens: A Case Report

S. SATHEESH BABU<sup>1</sup>, MUTHUNAGAI<sup>1</sup>, E. RAJESH<sup>2</sup> and N. ANITHA<sup>2</sup>

<sup>1</sup>Department of Oral Pathology, Sree Venkateswara Dental College, Ariyur, Pondy, India.

<sup>2</sup>Department of Oral Pathology and Microbiology,  
Sree Balaji Dental College & Hospital, Bharath University, Chennai, India.

DOI: <http://dx.doi.org/10.13005/bpj/642>

(Received: July 25, 2015; accepted: September 10, 2015)

### INTRODUCTION

Supernumerary tooth is an additional entity to the normal series and is seen in all the quadrants of the jaw<sup>1</sup>. The presence of supernumerary teeth is a dental anomaly of patterning and morphogenesis. Patterning alterations in human dentition often occur and are characterized by alterations in the number, size and shape of the teeth. Supernumerary teeth are developmental alterations of number and morphology that result in the formation of teeth in excess of the usual number<sup>2</sup>. Supernumerary teeth may occur as single (76–86%) double (12–73%) or multiple (<1%), unilaterally or bilaterally, and in one or both jaws<sup>3</sup>. The prevalence of supernumerary teeth in permanent teething oscillates from 0.5–3.8%, in comparison with 0.3–0.6% in primary teething. Supernumerary teeth appear with a higher frequency in males than in females with a 2:1 ratio. Supernumerary teeth also called hyperdontia, occur in both dentitions unilaterally or bilaterally and in one or both jaws. Multiple supernumerary teeth are in individuals with no other associated diseases or syndromes<sup>4</sup>. Supernumerary teeth are most frequently located in the maxillary incisor region (64.3%) with mesiodens accounting for 32.4% of such presentation<sup>5</sup>. A mesiodens is the most frequent type of supernumerary tooth. The frequency and prevalence of supernumerary teeth according to

dental group is given in [Table 1]<sup>6</sup>. The literature shows that 76 to 86% of nonsyndromic cases involve only one supernumerary tooth and that 12 to 23% of cases present two ST (2,10,11).

### Etiology

Many hypotheses have been proposed to explain the development of these teeth, including atavism, tooth germ dichotomy, hyperactivity of the dental lamina, and genetic and environmental factors<sup>10</sup>. The hereditary factor is believed to be important for the development of ST. There may be transmission of a recessive or dominant autosomal trait with incomplete penetrance, or the condition may be associated with an X chromosome<sup>14</sup>. Some ST are only impacted in the maxillary bones with no harmful effect and are usually identified accidentally during radiographic exams performed for other reasons<sup>4-6</sup>. However, in some cases they may cause complications, including retention or delayed eruption of some permanent teeth, diastemas, dislocation, dental rotation, root resorption, periodontal lesions, pulp necrosis of adjacent teeth, and formation of a dentigerous (odontogenic) cyst<sup>7,10,15</sup>. Thus, an early diagnosis and appropriate treatment are essential for a successful solution<sup>2</sup>.

### Classification

Classification of supernumerary teeth may be on the basis of position and morphology.

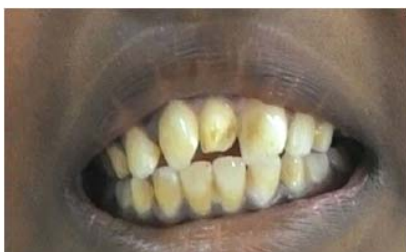Positional variations include:<sup>7</sup>

- Mesiodens: Present in the incisor region
- Paramolar: Present beside a molar
- Distomolar: Present distal to the last molar
- Parapremolar: Present beside a premolar

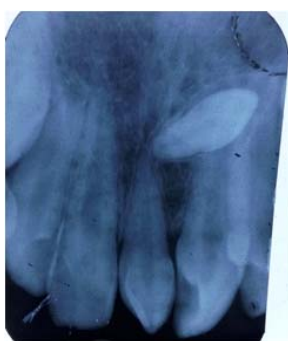Based on the morphology they can be of four types:<sup>1,8</sup>

- Conical: Peg shaped teeth
- Tuberculate: Made of more than one cusp or tubercle.
- They are barrel shaped, usually invaginated
- Supplemental: Resemble normal teeth may incisor, molar or molar
- Odontome: Does not resemble any teeth but is only a mass of dental tissue.

The ability to properly evaluate ST to determine their relation with adjacent teeth and other anatomical structures is important for the



**Fig. 1 : Showing presence of mesiodens**



decision about treatment, especially when extractions or ortho-surgical interventions are indicated.

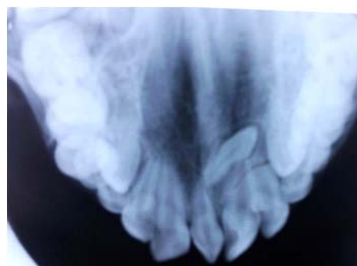
## DISCUSSION

### Case Presentation

A 11 year old boy came to the hospital with the chief complaint of forwardly placed teeth and psycho social problems. He had no relevant medical history and past dental history. On Extra oral examination, maxillary anteriors were protruberent with incompetent lips (fig 1).

Intra oral examination revealed presence of mesiodens and a mild diffuse swelling in the palatal aspect of maxillary anteriors extending from distal aspect of mesiodens to the distal surface of 12 and from gingival margin of mesiodens, 11 and 12 to 2 cm from junction of hard palate and soft palate, measuring 2x2 cm, surface was regular, color was normal with palatal mucosa with no secondary ulcerations. On palapation, swelling was hard and non-tender.

On radiographic investigation, both IOPA (fig 2) and occlusal films (fig 3) revealed radiopaque structure mimicking enamel, dentin and pulp of a tooth in between 11 and 12, suggesting the presence of mesiodens. Another radiopaque structure resembling a tooth was present at the root tip of mesiodens extending till 12, suggesting the presence of impacted supernumerary tooth in the palatal region.



scan fig(

**Fig 1 and 2 showing radiographically presence of mesiodens and supernumerary tooth**

**Table 1: Frequency and prevalence of the supernumerary teeth according to dental group[6]**

	Mesiodens	Premolars	Distomolars	Paramolars	Lateral incisor	Canine
Frequency	47-67%	8-9%	26%	15%	2.05%	0.40%
Prevalence	0.15-1.9%	0.09-0.29%	0.13-0.6%	0.08-0.5%	0.01-0.08%	0.002-0.02%

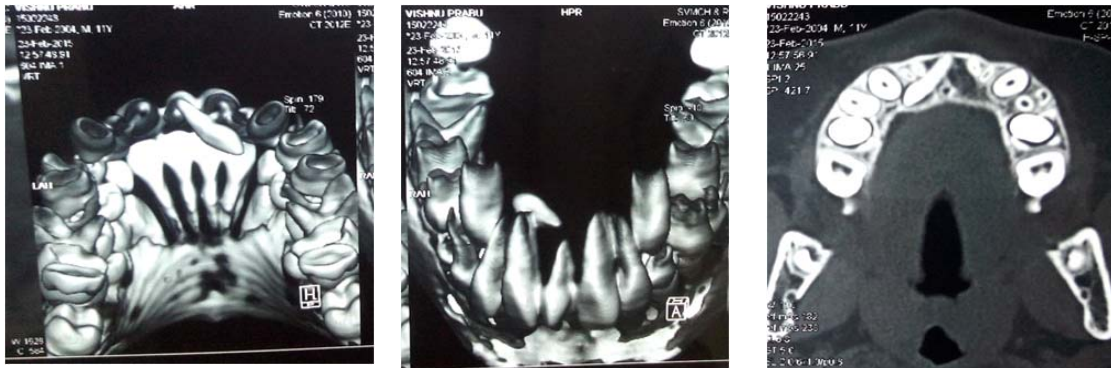


Fig. 4,5,6 CT showing presence of supernumerary tooth

4,5,6) was taken for confirmation and surgical assistance. Based on clinical findings and radiographic investigations, a final diagnosis of mesiodens and an impacted supernumerary tooth was made.

The treatment protocol was to remove the mesiodens and impacted supernumerary tooth surgically followed by orthodontic correction of malocclusion.

#### Treatment done

Surgical removal of the impacted supernumerary tooth was done through palatal

approach under local anaesthesia followed by extraction of mesiodens (fig 7). On post operative review, patient had no complaints of post operative pain or infection and is under orthodontic correction of malocclusion.

#### CONCLUSION

Supernumerary teeth can present in any region of the oral cavity. These may erupt or remain impacted and may lead to various complications. In this case the removal of odontome improved the esthetic status of the patient.

#### REFERENCES

- Mali S, Karjodkar FR, Sontakke S, Sansare K. Supernumerary teeth in non-syndromic patients. *Imaging Sci Dent*; **42**: 41–45 (2012).
- Rajab LD, Hamdan MA. Supernumerary teeth: review of the literature and a survey of 152 cases. *Int J Paediatr Dent*; **12**: 244-254 (2002).
- Klein OD, Oberoi S, Huysseune A, Hovorakova M, Peterka M, Peterkova R. Developmental disorders of the dentition: An update. *Am J Med Genet C Semin Med Genet*; **163**:318-332 (2013).
- Kawashita Y, Saito T. Nonsyndromic multiple mandibular supernumerary premolars: a case report. *J Dent Child*; **77**: 99-101 (2010).
- Fardi A, Kondylidou-Sidira A, Bachour Z, Parisi N, Tsirlis A. Incidence of impacted and supernumerary teeth - a radiographic study in a North Greek population. *Med Oral Patol Oral Cir Bucal*; **16**: E56-E61 (2011).
- Inchingolo F, Tatullo M, Abenavoli FM, Marrelli M, Inchingolo AD, Gentile M, et al.. Non-syndromic multiple supernumerary teeth in a family unit with a normal karyotype: case report. *Int J Med Sci*; **7**: 378-384 (2010).
- Ferres-Prado E, Prats-Armengol J, Ferres-Amat E. A descriptive study of 113 unerupted supernumerary teeth in 79 pediatric patients in Barcelona. *Med Oral Patol Oral Cir Bucal*; **14**: E146-E152 (2009).
- Diaz A, Orozco J, Fonseca M. Multiple hyperodontia: report of a case with 17 supernumerary teeth with non syndromic association. *Med Oral Patol Oral Cir Bucal*; **14**: E229-E231 (2009).
- Fernandez Montenegro P, Valmaseda Castellon E, Berini Aytes L, Gay Escoda C.

- Retrospective study of 145 supernumerary teeth. *Med Oral Patol Oral Cir Bucal*; **11**: E339-E344 (2006).
12. Liu DG, Zhang WL, Zhang ZY, Wu YT, Ma XC. Three-dimensional evaluations of supernumerary teeth using cone-beam computed tomography for 487 cases. *Oral Surg Oral Med Oral Pathol Oral Radiol Endod*; **103**:403-411 (2007).
  13. Hyun HK, Lee SJ, Ahn BD, Lee ZH, Heo MS, Seo BM, et al.. Nonsyndromic multiple mandibular supernumerary premolars. *J Oral Maxillofac Surg*; **66**: 1366-1369 (2008).
  14. Batra P, Duggal R, Parkash H. Nonsyndromic multiple supernumerary teeth transmitted as an autosomal dominant trait. *J Oral Pathol Med*; **34**:621-625 (2005).
  15. Wang XP, Fan J. Molecular genetics of supernumerary tooth formation. *Genesis*; **49**: 261-277.