

Knowledge, Attitude and Perception of Methods and Materials Used for Recording Posterior Palatal Seal among Dental Practitioners and Dental Students

NURUL SYAMIMI BINTI MOHD AZLAN SUNIL¹ and ASHISH R. JAIN²

¹Saveetha Dental College and Hospital, Saveetha University, Chennai, India.

²Department of Prosthodontics, Saveetha Dental College and Hospital, Saveetha University, Chennai, India.

*Corresponding author E-mail: dr.ashishjain_r@yahoo.com

<http://dx.doi.org/10.13005/bpj/1405>

(Received: February 19, 2018; accepted: March 09, 2018)

ABSTRACT

The posterior palatal seal (PPS) is an important structure aiding in retention of maxillary complete denture. Failure to properly record it may lead to seal failure, decrease retention and physiological violation of palate. Proper methods and materials to record PPS should be used to achieve good retention of denture and patient's comfort. To find out the most common methods and materials used for recording PPS among dental practitioners and dental students. 13 question questionnaire on knowledge, methods and materials to record PPS was prepared. 100 participants (50 dental practitioners, 50 dental students) from Saveetha Dental College, Saveetha University in Chennai was involved. The questionnaires were directly distributed and collected data was tabulated and analysed using Microsoft Excel 2013. 63% of participants correctly indicated pterygomaxillary seal and postpalatal seal as regions of PPS. 57% knew how to locate vibrating lines. 73% knew anterior vibrating line is cupid's bow shape. 42% prefer arbitrary scraping, however, 64% indicated that it is the least accurate method. 49% and 44%, respectively, prefer IOWA wax and Korecta wax to record PPS. In a conventional technique, 73% prefer using ball-end of T-burnisher. 28% indicated butterfly shaped with notching of hamular notch as common form of PPS. 35% agreed that class 1 variation of PPS is the most common. 26% indicated the anterior vibrating line is 1.31mm distal to fovea palatine. 31% agreed lateral part of cupid's bow has the highest compressibility. 45% indicated 5-12mm as anteroposterior width of PPS. The most preferred technique was arbitrary scraping. Most participants prefer IOWA wax and Korecta wax in case of fluid wax technique and flat-end part of T-burnisher is preferred in conventional technique. Results on knowledge of anatomical landmarks and parameter of PPS indicate that there is a need to emphasize on the importance of PPS with proper learning.

Keywords: Denture retention, Knowledge on PPS, Materials to record PPS, Methods of recording PPS, PPS survey.

INTRODUCTION

According to Glossary of Prosthodontics Terms, posterior palatal seal is the seal at the posterior border of a maxillary prosthesis. Posterior palatal seal area is the soft tissue area at or beyond

the junction of the hard and soft palates on which pressure, within physiological limits, can be applied by a denture to aid in retention¹. The retention of the denture is a matter of great satisfaction to a dentist and more importantly, an utmost interest to the patient. A successful retention is achievable if



This is an Open Access article licensed under a Creative Commons Attribution-NonCommercial-ShareAlike 4.0 International License (<https://creativecommons.org/licenses/by-nc-sa/4.0/>), which permits unrestricted Non Commercial use, distribution and reproduction in any medium, provided the original work is properly cited.

the correct techniques and materials are put to use during treatment to fulfil the needs and expectations of the patient.

Patients expect a good prosthesis which can work efficiently during speech and mastication and be well-retained in the mouth for a long duration. Therefore, the importance of extension of complete dentures has been well-established for various reasons. The posterior palatal seal functions to provide retention and stability of a well-adapted denture through forces of adhesion, cohesion and interfacial surface tension by providing a proper seal, prevents food accumulation between posterior border of denture and soft palate, to reduce the tendency of gag, to make the sunken distal border of the denture less noticeable to the tongue, to supply a thickened area that provides added strength across the denture and to compensate for polymerization²⁻⁴. Additional functions of posterior palatal seal which have been described by Weintraub⁵ are increase in confidence and comfort to the patient by enhancing retention, provides a positive posterior contact and thus prevents the final impression material from sliding down into the pharynx. Although forces such as adhesion and cohesion, interfacial surface tension, capillary attraction and viscosity of the saliva may have been recognized to aid in retention of a denture, these forces are capable to resist only those forces that act perpendicular to the denture base. However, atmospheric pressure helps to counteract those tipping thrusts and lateral torque which tend to dislodge the denture. The displacement of the denture is prevented by a partial vacuum that is formed between the supporting tissues and the denture base that will resist lateral torque. Zurasky and Duke⁶ emphasized the fact that retention and stability obtained by adhesion and cohesion resist the forces, which are directed in vertical direction. A well-fitting and retentive complete denture requires a well-fitting tissue surface, a peripheral border compatible with the muscles and tissues which make up the mucobuccal and mucolabial spaces so that a peripheral seal is created by the soft tissue draping over them. It is usually obtained by labial and buccal seal. In the posterior region, it is mainly by the posterior palatal seal⁷. At the posterior extension of the maxillary denture, where the tissues are less compliant, special attention is required to make the seal effective. This is the postdam region, where the denture is designed to affect a posterior

palatal seal⁸. Skinner demonstrated experimentally the importance of posterior palatal seal and stated: "The most effective addition to increase retention is the post dam"⁹. Despite the literature based recommendation regarding the relevance of posterior palatal seal in fabricating dentures, the location and preparation of it is frequently neglected by clinicians and dental students¹⁰. Many dentures have failed due to improper establishment of distal limit and improper recording of posterior palatal seal. Recording posterior palatal seal without reference to the anatomical landmarks of the mouth may result in error of location and preparation on the master cast.

Various methods and materials to record posterior palatal seal and reproducing it in the maxillary denture have been introduced, such as the conventional technique, fluid wax technique, arbitrary technique, and extended palate technique¹¹. Classification of techniques of recording posterior palatal seal by Hardy and Kapoor² is divided in to three, which are functional, semi-functional and empirical technique. In the functional technique, the final impression is border molded in posterior palatal seal area with soft stick modelling compound or wax by sucking movements performed by the patient. As for semi-functional technique, border molding is done by the dentist itself and the cast is grooved to the desired depth in empirical technique. Each technique has its own advantages and disadvantages. Recording the posterior palatal seal is commonly performed by locating the posterior vibrating line in the patient's mouth and transferring in to the master cast, followed by arbitrarily scribing the cast before fabricating the denture¹²⁻¹⁶. Based on a previous study, 87.5% of dental schools in the Canada and United states implement arbitrary scribing to record posterior palatal seal on the cast,¹⁷ although arbitrary scribing of the master cast is considered to be the least reliable method¹⁸. For the establishment of posterior palatal seal at final impression stage, the fluid wax technique is the technique of choice. Nevertheless, fluid wax technique¹⁹ comes with a few disadvantages such as more time is required for impression appointment, handling the materials may be difficult, a heating unit is needed for the purpose of wax conditioning, and boxing procedure of cast formation requires proper care to prevent any distortion of the carefully added posterior palatal seal wax.

Choices of method to be used and timing depends on one's preference and experience. Hence, this study aims to find out the most common methods and materials used for recording posterior palatal seal among dental practitioners and dental students.

MATERIALS AND METHODS

An original pretested questionnaire on knowledge, attitude and perception of methods and materials to record posterior palatal seal was prepared. The questionnaire includes age of participants, gender and the year of study in case of student participants. The questionnaire consist of 13 questions regarding knowledge on anatomical landmarks and surrounding structures of posterior palatal seal, and perception and knowledge on methods and materials available to record posterior palatal seal. As seen in Figure 1, the sample size of this questionnaire-based study is 109 population. This study was conducted with 100 participants, thus, it is sufficient for the required sample size.

50 dental practitioners and 50 dental students were involved in the survey. Dental students were of third years, fourth years and interns and as for dental practitioners, the questionnaires

were given at random to all faculties. Anatomical landmarks and surrounding structures of posterior palatal seal is of great importance when locating and recording the posterior palatal seal. Thus, questions regarding it were included in the survey to assess the participants' knowledge on the structures and their priority towards it. The questionnaires were directly distributed to the participants and filled up questionnaires were immediately collected on site. The collected data was analysed and tabulated in Microsoft Excel 2013. All 100 participants responded to the survey, yielding a response rate of 100%. The subjects are between the ages of 20 to 46 years.

RESULTS

A total of 100 dental practitioners and dental students from Saveetha Dental College participated in this study. The response rate of participants was 100%. Among 100 participants, 58 of them were female (27-practitioners, 31-students) and 42 were male (23-practitioners, 19-students) participants, aged between 20 to 46 years. Out of 50 dental students, 21 (42%) of them are interns, 18 (36%) are in their fourth year and the remaining 11 (22%) are third year students. The results were gathered through the questionnaires and they are as followed.

Sample Size for Frequency in a Population

Population size(for finite population correction factor or fpc)(N):	150
Hypothesized % frequency of outcome factor in the population (p):	50%+/-5
Confidence limits as % of 100(absolute +/- %)(d):	5%
Design effect (for cluster surveys-DEFF):	1
Sample Size(n) for Various Confidence Levels	

ConfidenceLevel(%)	Sample Size
95%	109
80%	79
90%	97
97%	114
99%	123
99.9%	132
99.99%	137

Equation

Sample size $n = [DEFF * Np(1-p)] / [(d^2 / Z^2_{1-\alpha/2} * (N-1) + p*(1-p)]$

Results from OpenEpi, Version 3, open source calculator--SSPropor
 Print from the browser with ctrl-P
 or select text to copy and paste to other programs.

Fig. 1: Sample size calculation

Table 1: Questionnaire on Knowledge, Attitude and Perception on Methods and Materials used for Recording Posterior Palatal Seal among Dental Practitioners and Dental Students**No. of Questions**

1. Based on anatomical landmark, which two regions make up the posterior palatal seal?
 - a) Hamular notch and postpalatal seal
 - b) Pterygomaxillary seal and postpalatal seal
 - c) Maxillary tuberosity and postpalatal seal
 - d) Pterygomaxillary seal and maxillary tuberosity
2. Are you aware of how to locate the anterior and posterior vibrating line?
 - a) Yes
 - b) No
3. What is the shape of anterior vibrating line?
 - a) Butterfly-shaped
 - b) Oval-shaped
 - c) Cupid's bow shaped
 - d) Triangular-shaped
4. While recording posterior palatal seal, should PPS extend in to mid palatine fissure if it is present?
 - a) Yes
 - b) No
5. Which techniques do you prefer to use when recording the PPS?
 - a) Conventional technique
 - b) Fluid wax technique
 - c) Arbitrary scraping of master cast
 - d) Extended palate technique (Silverman)
 - e) Adding PPS to extending denture
 - f) Others: _____
6. Among the four techniques stated below, which is the least accurate method to mark the posterior palatal seal?
 - a) Conventional technique
 - b) Fluid wax technique
 - c) Arbitrary scraping
 - d) Extended palate technique (Silverman)
7. Which material do you prefer to use when recording PPS with fluid wax technique?
 - a) IOWA wax
 - b) Korecta wax
 - c) Adaptol
 - d) H-L physiologic paste
8. Which part of the T-burnisher do you prefer to use when recording PPS with conventional technique?
 - a) Ball-end
 - b) Flat-end
 - c) Handle end
9. Out of various forms of posterior palatal seal which is more common?
 - a) Single bead scribed on the posterior vibrating line
 - b) Double line scribed in the anterior and posterior vibrating line
 - c) Butterfly shaped posterior palatal seal
 - d) Butterfly shaped posterior palatal seal with notching of posterior vibrating line
 - e) Butterfly shaped posterior palatal seal with notching of hamular notch.
10. Most common Variations used with different shaped soft palate based on the classification.
 - a) Class 1: A butterfly shaped posterior palatal seal with 3-4 mm wide
 - b) Class 2: Posterior palatal seal is narrow with 2-3 mm of width
 - c) Class 3: A single beading made on the posterior vibrating line
11. Location of posterior palatal seal is not consistent and show lot of variation but on an average anterior vibrating line is _____mm distal to fovea palatine.
 - a) 1.31mm
 - b) 1.39mm
 - c) 1.57mm
 - d) 2.1mm
12. Which part of posterior palatal seal has highest compressibility?
 - a) Midpalatine raphe
 - b) Hamular notch
 - c) Lateral part of cupid's bow
 - d) All of the above
13. Anteroposterior width of posterior palatal seal is
 - a) 5-12mm
 - b) 8-10mm
 - c) 10-12mm
 - d) less than 5mm

As seen in Figure 2, 63% of the participants correctly indicated that the pterygomaxillary seal and postpalatal seal are two regions which make up the posterior palatal seal, whereas 24% answered 'hamular notch and postpalatal seal', 9% chose 'maxillary tuberosity and postpalatal seal' and remaining 4% went with 'pterygomaxillary seal and maxillary tuberosity'.

The participants were asked if they were aware on how to locate the anterior and posterior

vibrating line. As seen in Figure 3, over half of the participants surveyed (57%) were aware on how to locate the anterior and posterior vibrating line while 43% reported not being aware of it.

When asked about the shape of anterior vibrating line, as seen in Figure 4, nearly four fifth of the participants (73%) were aware of the shape of anterior vibrating line and correctly indicated cupid's bow shape, however, 21% went with butterfly shape and 6% went with oval shape. None of the participants chose triangular shape as their answer.

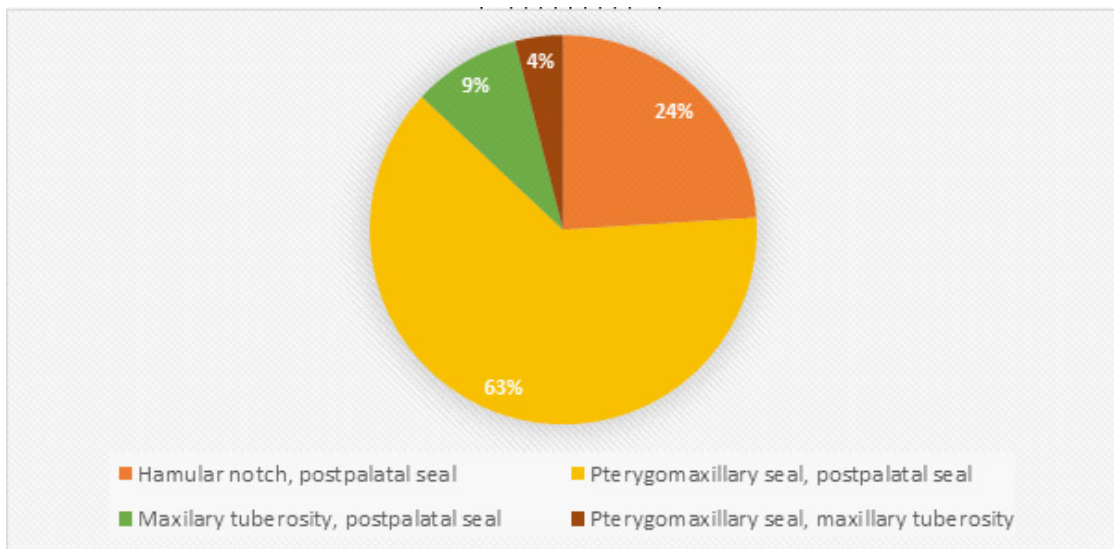


Fig. 2: Percentage of results on regions which make up the posterior palatal seal

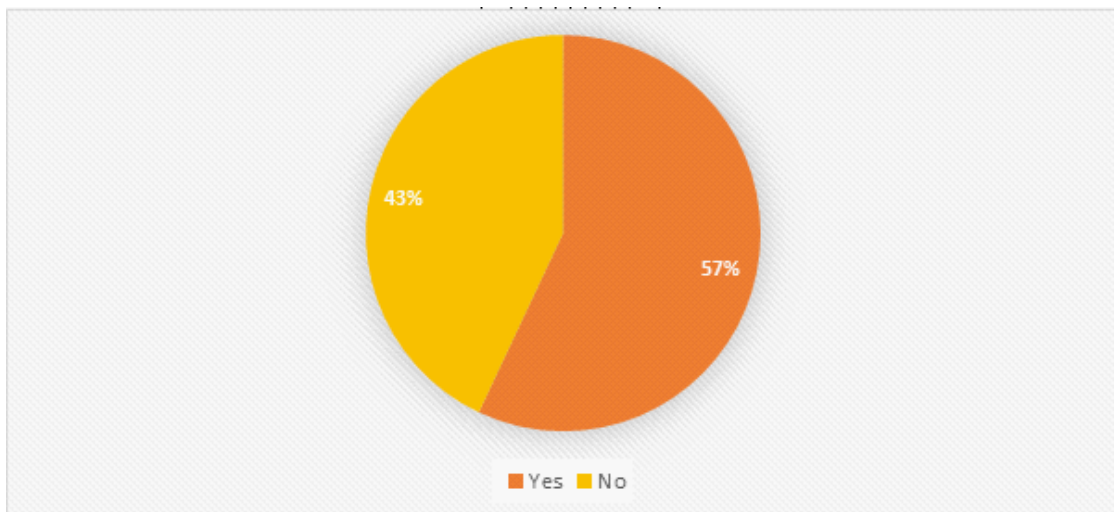


Fig. 3: Percentage of results on awareness on how to locate posterior palatal seal

The participants were asked whether or not the posterior palatal seal should extend in to the mid palatine fissure while recording the posterior palatal seal if it is present. Figure 5 shows that 81% agreed that the posterior palatal seal should be extended in to the mid palatine fissure if it is present and the remaining 19% decided the opposite.

As shown in Figure 6, almost half of the participants surveyed (42%) reported arbitrary scraping technique as preferred technique, 25% prefer fluid wax technique to record posterior palatal seal, 21% would use conventional technique, and

only 7% and 5%, respectively, would prefer to use extended palate technique (Silverman technique) and adding posterior palatal seal to extending denture.

As shown in Figure 7, among the four techniques - conventional technique, fluid wax technique, arbitrary scraping technique and extended palate technique (Silverman technique), arbitrary scraping technique was indicated as the least accurate method to mark posterior palatal seal by a majority of the participants (64%) while 19% and 12% went with fluid wax technique and conventional

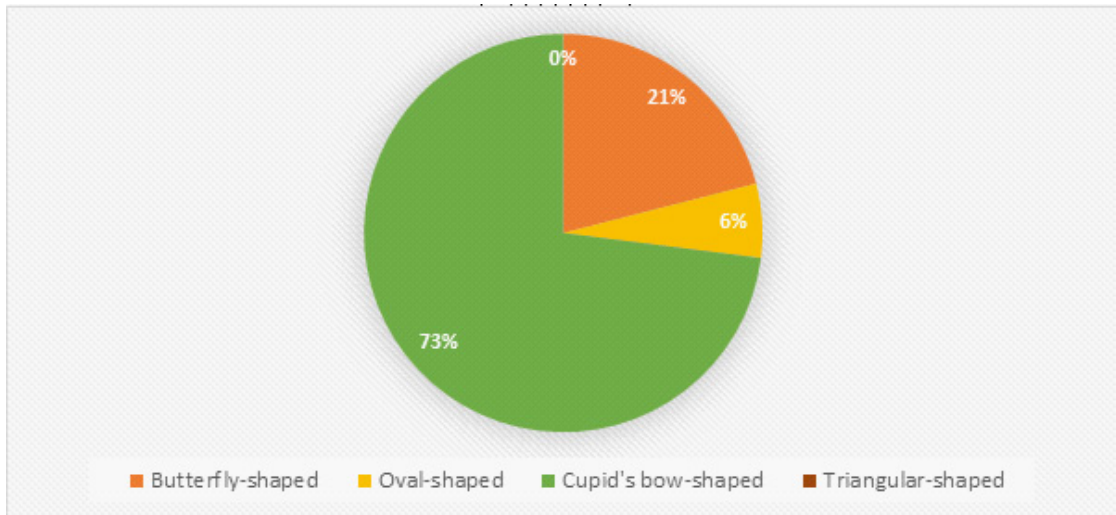


Fig. 4: Percentage of results on the shape of anterior vibrating line

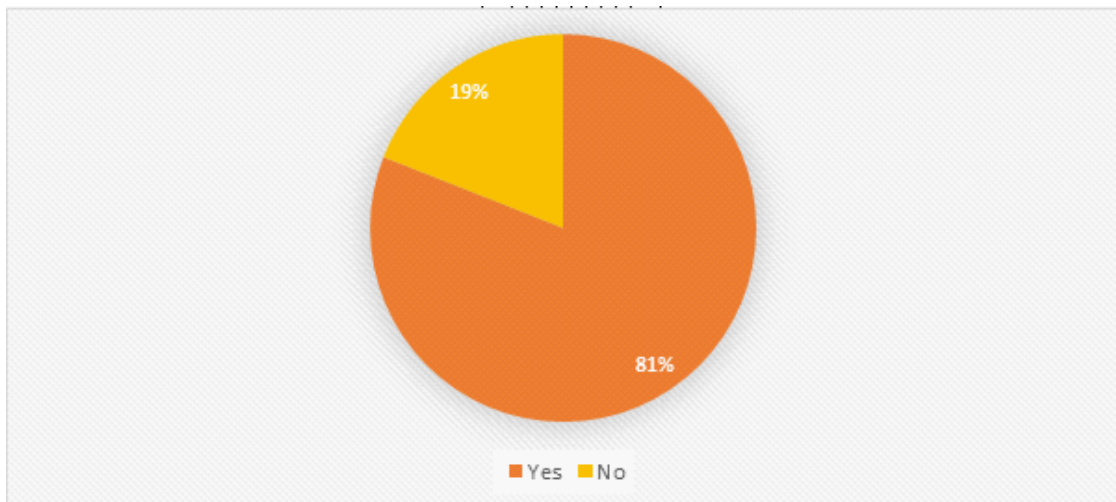


Fig. 5: Percentage of results on extension of posterior palatal seal into mid palatine fissure

technique respectively as least accurate method and the remaining 5% reported extended palate technique.

When asked on which materials they prefer to use when using fluid wax technique, as seen in Figure 8, 44% of participants prefer to use Korecta wax when recording posterior palatal seal by fluid wax technique. IOWA wax is preferred by 49% of participants, 7% selected adaptol and none prefer to use H-L physiologic paste.

The participants were asked on which part of the T-burnisher to they prefer to use when recording posterior palatal seal with conventional technique. As seen in Figure 9, most of the participants (73%) prefer to use the flat-end of t-burnisher and only 27% prefer the ball-end.

Participants were asked on the most common form posterior palatal seal, in which as seen in Figure 10, 32% of participants reported 'butterfly

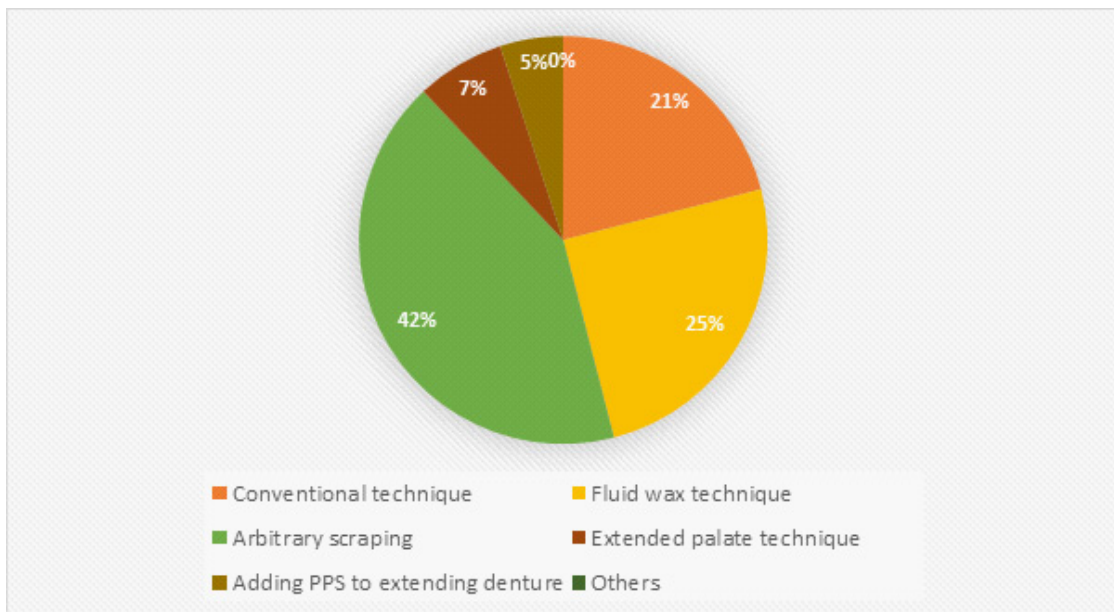


Fig. 6: Percentage of results preferred techniques to record posterior palatal seal

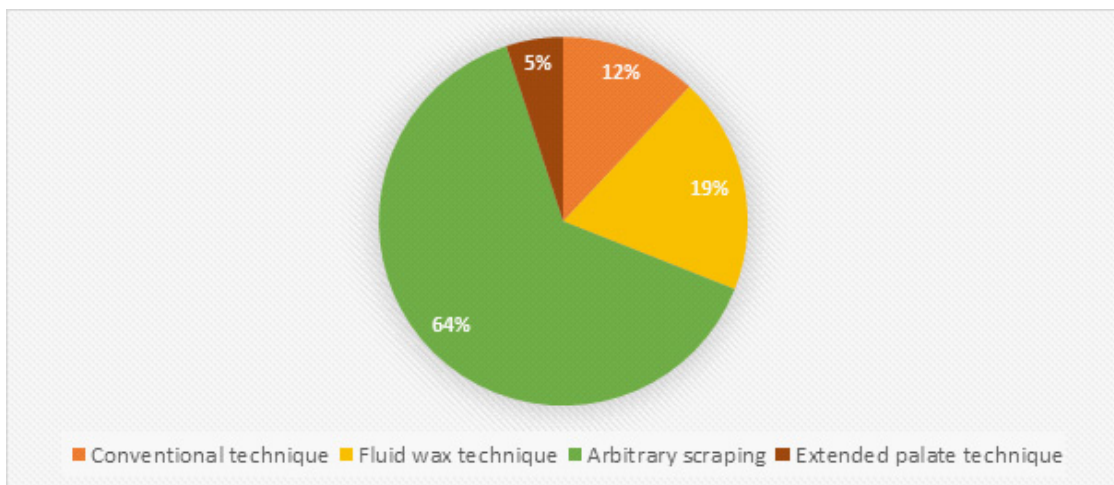


Fig. 7: Percentage of results on least accurate method to mark posterior palatal seal

shape' as most common form of posterior palatal seal, whereas 18% and 14%, respectively, answered 'double line scribed in the anterior and posterior vibrating line' and 'butterfly shape with notching of posterior vibrating line'. 8% answered 'single bead scribed on the posterior vibrating line'. However, only 28% of the participants correctly indicated that the butterfly shaped posterior palatal seal with notching of hamular notch is the most common form of posterior palatal seal.

narrow with 2-3mm of width' as the common variation used with different shaped soft palate based on the classification. Only 35% responded with 'Class 1: A butterfly shaped posterior palatal seal with 3-4mm wide' and the rest of the participants (13%) went with 'Class 3: A single beading made on the posterior vibrating line'.

Figure 11 shows over half of the participants (52%) answered 'Class 2: Posterior palatal seal is

The participants were asked on the average distance of anterior vibrating line to fovea palatine. Figure 12 shows option (b) and (c) (1.39mm and 1.57mm respectively) had an equal response of

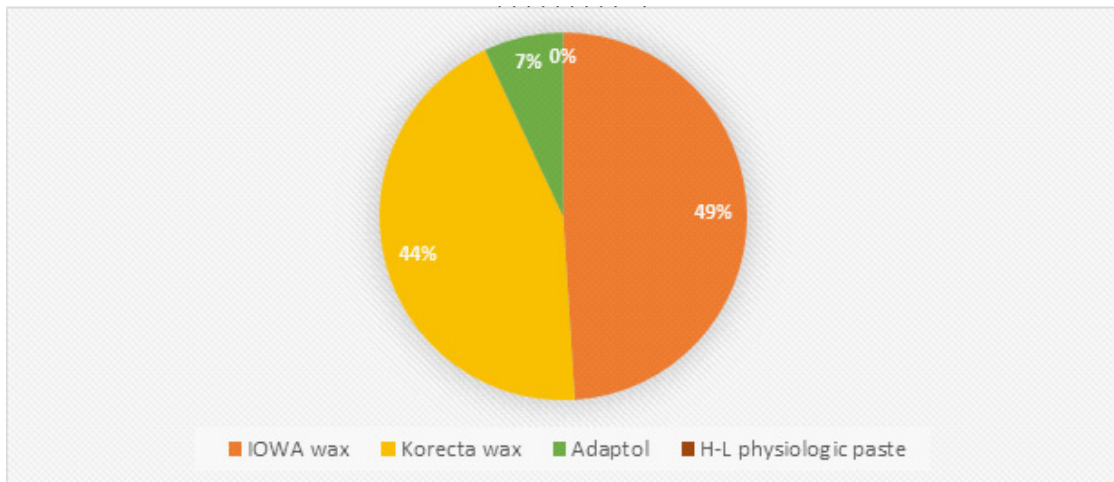


Fig. 8: Percentage of results preferred material in fluid wax technique

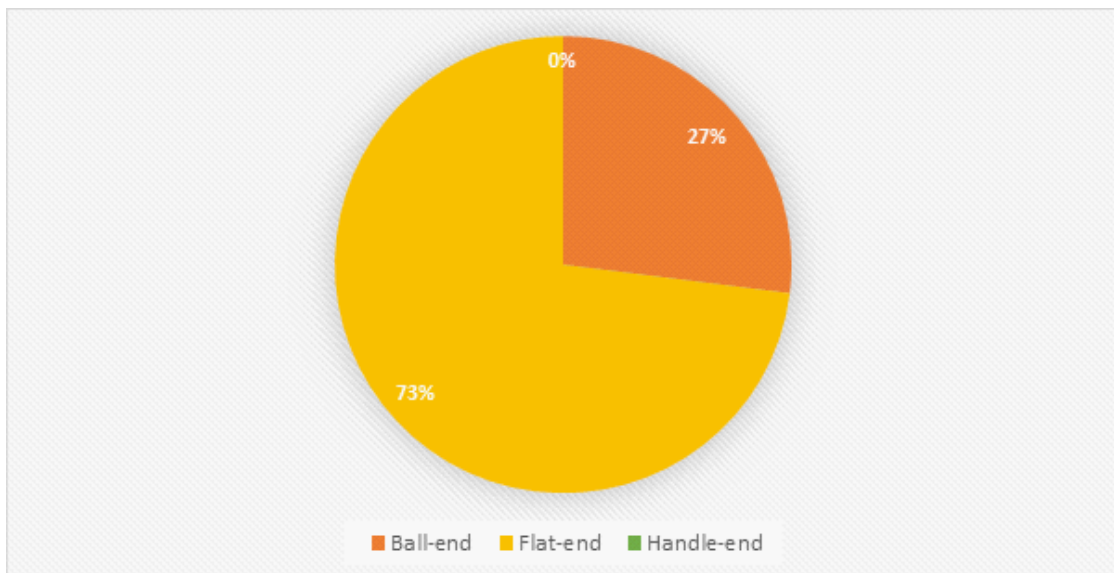


Fig. 9: Percentage of results preferred part of T-burnisher to record posterior palatal seal

31% of the participants, 26% responded '1.31mm' and 12% answered '2.1mm' distal to fovea palatine.

As seen in Figure 13, 36% indicated that hamular notch is the part of posterior palatal seal with highest compressibility, 20% responded with option (a)-mid palatine raphe, 31% of the participants

correctly answered 'lateral part of cupid's bow' and few of them (13%) went with option (d)-all of the above.

Figure 14 shows less than half the participants surveyed (45%) agreed on 5-12mm as the anteroposterior width of posterior palatal seal,

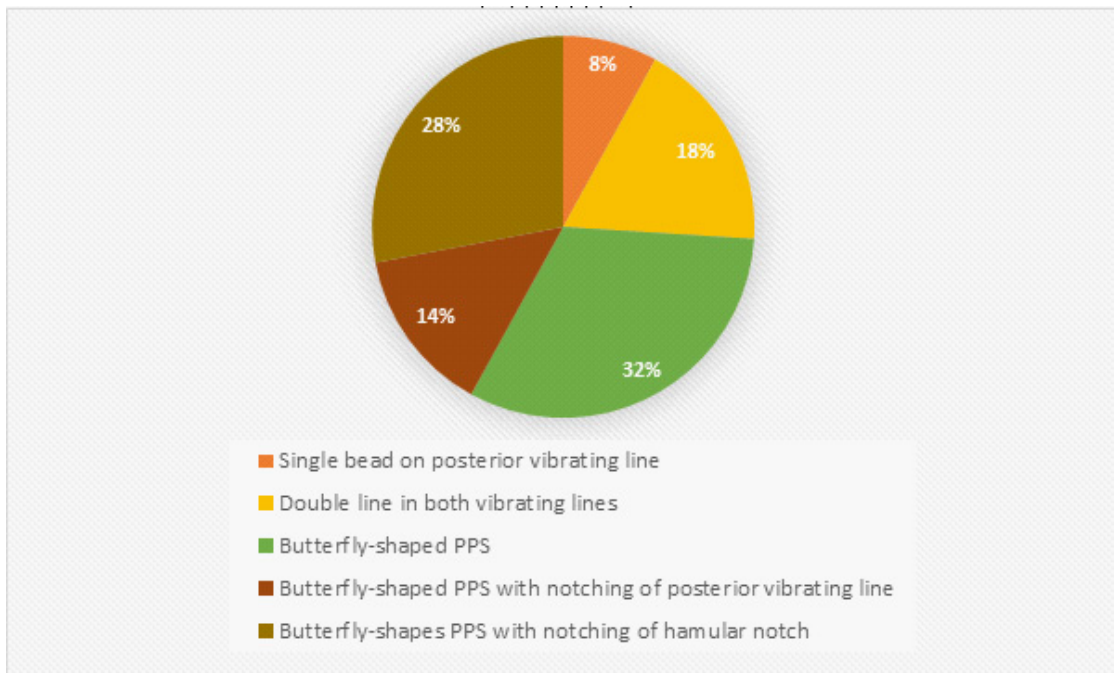


Fig. 10: Percentage of results the most common form of posterior palatal seal

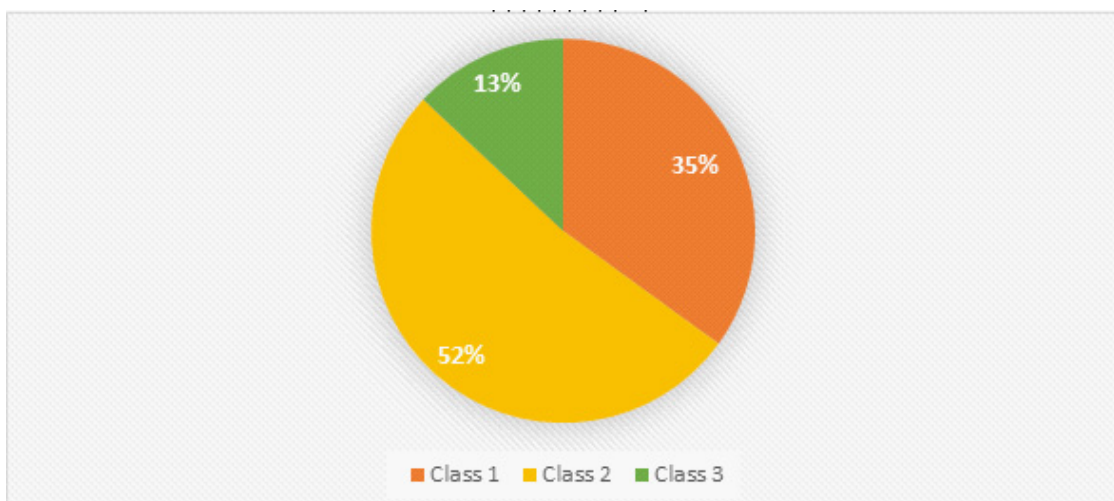


Fig. 11: Percentage of results most common variations with different shaped soft palate based on classification?

around two fifth of the participants (31%) responded '8-10mm', 6% answered '10-12mm' and 18% responded with 'less than 5mm'.

DISCUSSION

The results of this survey of show that most of the participants do possess knowledge on the anatomical landmarks and surrounding structures of posterior palatal seal. However, most

of them do not possess knowledge on parameters of posterior palatal seal such as size, shape, location and compressibility. The materials and methods used to record posterior palatal seal vary among them. Most of the participants had knowledge on the regions which make up the posterior palatal seal, which is the pterygomaxillary seal and post palatal seal. Pterygomaxillary seal extends through pterygomaxillary notch continuing 3-4 mm anterolaterally, approximating the mucogingival

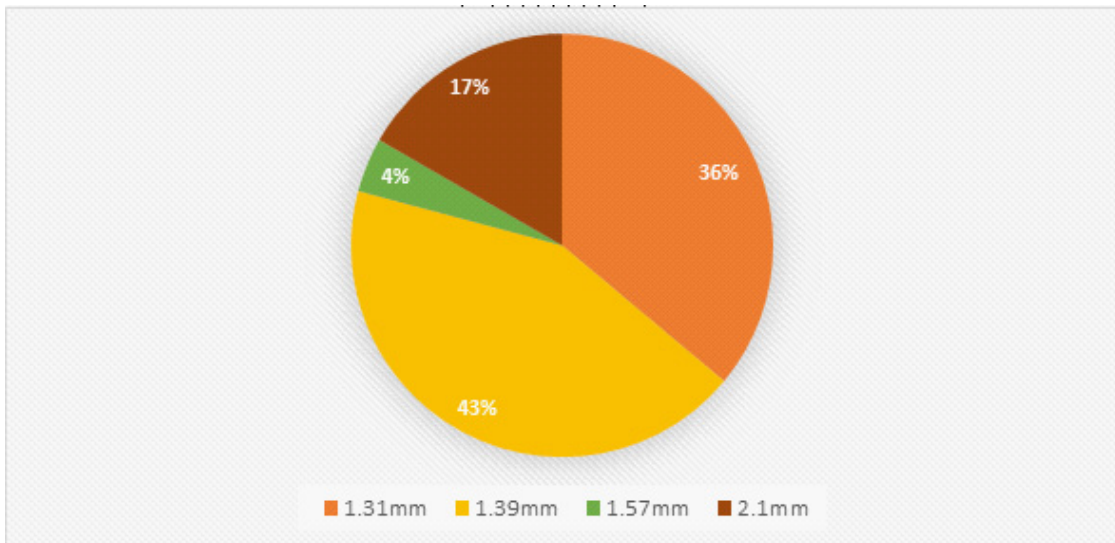


Fig. 12: Percentage of results on distance of anterior vibrating line to fovea palatine

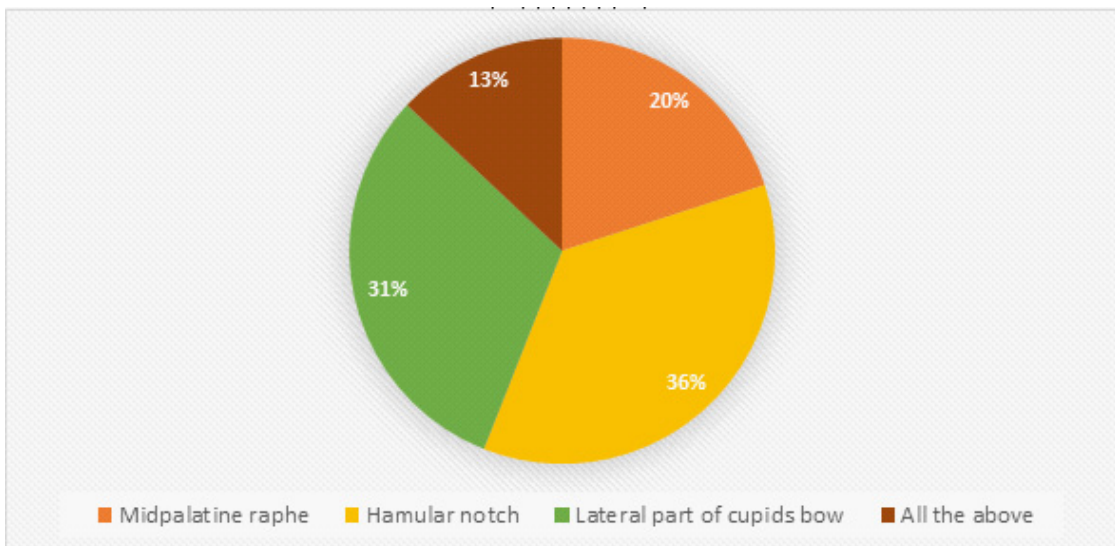


Fig. 13: Percentage of results on part of posterior palatal seal with highest compressibility

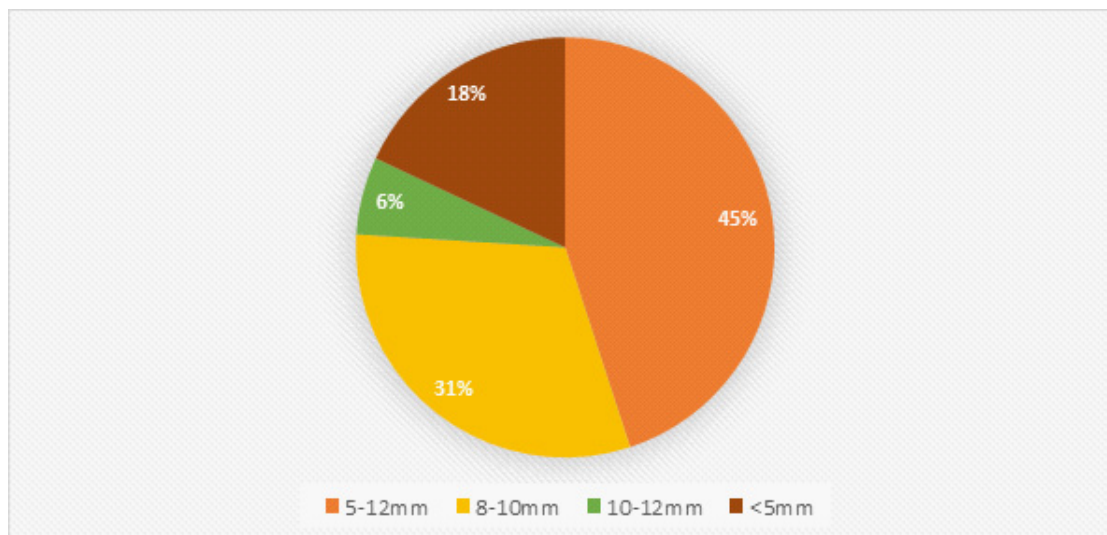


Fig. 14: Percentage of results on anteroposterior width of posterior palatal seal

junction¹. Hardy and Kapur² mentioned that it occupies the entire width of hamular notch which is covered by pterygomaxillary fold. The postpalatal seal is the area between the anterior and posterior vibrating line found medially from one tuberosity to other and appears as a cupid's bow, which is correctly indicated by 73% of the participants. Over half of the participants (5%) were aware on how to locate the anterior and posterior vibrating line, although it has been thought in second year and in depth during the fourth year of study. According to Sear, the anterior vibrating line is not the junction of hard and soft palate. However, according to Gerald S. Wintraub, it is usually located in the junction of soft and hard palate⁵. Based on a previous study by Rashedi, B., & Petropoulos, V. C. (2003)²⁰, most dental schools in the US (80%) teach a combination of phonation of the "ah" sound with other method such as blowing the nose and using fovea palatine as a guide, in locating posterior vibrating line. In order to achieve obtain acceptable stability and retention of denture, the denture should be perfectly adapted and proper seal should be established². A satisfying majority of participants (81%) do know while recording posterior palatal seal, it should extend into the mid palatine fissure if it is present. This is to provide a good peripheral seal³.

Less than half of the participants (42%) prefer to use arbitrary scraping technique to record posterior palatal seal, although it is the least

accurate technique as it has high potential of over postdamming and it is not physiologic²¹. 64% of the participants were aware of the inaccuracy of arbitrary scraping technique. Similarly, a previous study by Chen et al., reported most dental schools in the United States and Canada (87.5%) teach arbitrary scribing of master cast although they are aware arbitrary scribing of mater cast is considered by some to be the least accurate method and leaves a chance at insertion appoint since it relies of dentist's recollection of palatal configuration and tissue compressibility²². 21% of participants prefer conventional, and 25% prefer to use fluid wax technique. Based on a literature review, conventional technique provides a highly retentive trial base, gives psychological security to patient that retention will not be a problem, dentist is able to understand the retentive qualities of final denture, and the posterior extension of the denture can be understood by the patient, but, it has more potential for over compression of tissue and not a physiological technique¹⁰. However, fluid wax technique avoids over compression of tissue and it is a physiological technique besides increasing retention at an early stage by incorporating posterior palatal seal into trial denture base¹⁰. Others would prefer extended palate technique (7%) and another technique which is adding posterior palatal seal to extending denture (5%). Fluid wax technique uses waxes that have low melting point for ease of use intraorally without discomfort or trauma to the patient, low distortion

and rigidity at room temperature, high flow rate at mouth temperature (98.6°F), smooth texture and ease of adding additional layers without demarcation and hardens readily when chilled^{7,11}. Impression waxes used in fluid wax technique are IOWA wax developed by Dr. Earl S. Smith, Korecta wax no. 4 by Dr. O. C. Applegate, H-L physiologic paste by Dr. C.S. Howkins and adaptol by Dr. Nathen G. Kyne. Korecta wax and IOWA wax were preferred by 44% and 49% of the participants respectively, and only 7% preferred adaptol.

A study by Lye¹¹ in 100 randomly selected subjects found the fovea palatine were posterior to the vibrating line in 13% of the cases, 17% coincide with it and 70% lay anterior to it. Location of posterior palatal seal is not consistent and show lot of variation but on an average anterior vibrating line is 1.31 mm distal to fovea palatine²³. Only 26% of the participants correctly indicated the location of vibrating line to fovea palatine. A lot of variation has been found in the posterior palatal seal area. Midpalatal raphe and hamular notch has been observed to have low compressibility. Lateral part of cupid's bow has been observed as having the highest compressibility, which is correctly responded by 31% of the participants. With regards to size, only 45% indicated the anteroposterior width of posterior palatal seal is 5-12mm. On an average, the dimension of posterior palatal seal was 2mm at the midpalatal region and hamular notch, which was claimed by Hardy and Kapur². A previous study performed by Silverman evaluated the posterior palatal seal clinically, histologically and radiographically, and he found that 8.0mm (with range of 5-12mm) is the greatest mean anteroposterior width of posterior palatal seal²¹. This indicates that the participants had poor knowledge on parameters of posterior palatal seal

such as location, size, shape and compressibility. Clinicians should appreciate that the shape and dimension of posterior palatal seal cannot be only arbitrarily made on edentulous cast because it needs to be physiologically compatible with the tissues at rest and during function. A previous study observed that dental students have an intermediate level of confidence in selecting various techniques available for recording posterior palatal seal²⁴. Students need to be taught that recording posterior palatal seal is a clinical procedure and should not be ignored and delegate the task to laboratory technicians. As mentioned by Laney and Gonzalez²⁵, to assign the laboratory technician this responsibility is a breach of the patient's faith in the diagnostic ability of the dentist.

CONCLUSION

The finding of this survey showed that the preferred materials and methods to record posterior palatal seal vary among them but one technique which was mostly preferred was the arbitrary scraping technique. Most of them had common preference on materials to be used. The participants have an acceptable knowledge on anatomical landmarks and surrounding structures of posterior palatal seal. However, knowledge on specific parameters such as size, shape, location and compressibility was poor. This indicates that there is a need to emphasize on the importance of posterior palatal seal with proper learning as it plays an important role in complete denture stability and retention and patient's satisfaction. Without knowledge on posterior palatal seal, there will be an increase chance of errors that will affect the success of a complete denture prostheses and patient's satisfaction.

REFERENCES

1. The Glossary of Prosthodontic Terms 8th ed. *J Prosthet Dent*; **95**: 10-81 (2005).
2. Hardy IR, Kapur KK. Posterior border seal—its rationale and importance. *Journal of Prosthetic Dentistry*; **8**(3):386-97 (1958).
3. Nallaswamy D. Textbook of prosthodontics. 2nd ed. Jaypee Brothers Medical Publishers (P) Ltd; (2017).
4. Bindhoo YA, Thirumurthy VR, Jacob SJ. Posterior Palatal Seal: A Literature Review. *International Journal of Prosthodontics and Restorative Dentistry*; **1**(2):108-14 (2011).
5. Weintraub GS. Establishing the posterior palatal seal during the final impression procedure: a functional approach. *The Journal of the American Dental Association*;

- 94(3):505-10 (1977).
6. Zurasky JE, Duke ES. Improved adhesion of denture acrylic resins to base metal alloys. *Journal of Prosthetic Dentistry*; **57**(4):520-4 (1987).
 7. Ettinger RL, Scandrett FR. The posterior palatal seal. A review. *Australian Dental Journal*.; **25**: 197-200 (1980).
 8. Schwarz WD. The post dam. *Dental Update*; **18**: 26-30 (1991).
 9. Skinner EW, Campbell RL, Chung P. A clinical study of the forces required to dislodge maxillary denture bases of various designs. *The Journal of the American Dental Association*.; **47**(6):671-80 (1953).
 10. Goyal S, Goyal MK, Balkrishnan D, Hegde V, Narayana AI. The posterior palatal seal: Its rationale and importance: An overview. *European Journal of Prosthodontics*.; **2**(2):41 (2014).
 11. Lye TL. The significance of the fovea palatini in complete denture prosthodontics. *Journal of Prosthetic Dentistry*.; **33**(5): 504-10 (1975).
 12. Avant WE. A study of some factors associated with denture retention. *The Journal of prosthetic dentistry*.; **29**(4):383-9 (1973).
 13. Maison WG. Denture outline form. *The Journal of the American Dental Association*.; **59**(5):938-43 (1959).
 14. Hicky JC, Zarb GA, Bolender CL. Boucher's prosthodontic: treatment for edentulous patient. 8th ed. St. Louis: Mosby publishers; 411-5 (1980).
 15. Naylor WP, Stephens VA. Location and transfer of the vibrating line: clinical and laboratory techniques. *Quintessence of dental technology*.; **10**(9): 557 (1986).
 16. Naylor WP, Rempala JD. The posterior palatal seal—its forms and functions (II)—Design and cast preparation. *Quintessence of dental technology*. **10**(8):489-92 (1986).
 17. Chen MS, Welker WA, Pulskamp FE, Crosthwaite HJ, Tanquist RA. Methods taught in dental schools for determining the posterior palatal seal region. *Journal of Prosthetic Dentistry*; **53**(3):380-3 (1985).
 18. Winkler S, editor. Essentials of complete denture prosthodontics. 2nd ed. Year Book Medical Publishers; **119** (1988).
 19. Winkler S. Essentials of complete denture prosthodontics. WB Saunders Company; 183-90 (1979).
 20. Rashedi B, Petropoulos VC. Current concepts for determining the postpalatal seal in complete dentures. *Journal of Prosthodontics*.; **12**(4):265-70 (2003).
 21. Winkler S. Essentials of complete denture prosthodontics. WB Saunders Company; 171-92 (1979).
 22. Chen MS, Welker WA, Pulskamp FE, Crosthwaite HJ, Tanquist RA. Methods taught in dental schools for determining the posterior palatal seal region. *Journal of Prosthetic Dentistry*.; **53**(3):380-3 (1985).
 23. Silverman SI. Dimensions and displacement patterns of the posterior palatal seal. *Journal of Prosthetic Dentistry*.; **25**(5):470-88 (1971).
 24. Swathy S, Ashish R.J. Knowledge and Self Perception among Dental Students (Interns) about Procedures Involved in Complete Denture Fabrication. *The Journal of Pharmaceutical Sciences and Research*.; **9**(5):708-11 (2017).
 25. Laney WR, Gonzalez JB. The maxillary denture: its palatal relief and posterior palatal seal. *The Journal of the American Dental Association*.; **75**(5): 1182-7 (1967).