

An Efficient Detection System For Screening Glaucoma In Retinal Images

N.B.PRAKASH^{1*} and D.SELVATHI²

¹Department of Electrical and Electronics Engineering, national Engineering College, India.

²Department of Electronics and Communication Engineering, Mepco Schlenk Engineering College, India.

* Corresponding author E-mail: nbprakas@gmail.com

<http://dx.doi.org/10.13005/bpj/1130>

(Received: December 19, 2016; accepted: January 02, 2017)

ABSTRACT

Glaucoma is the retinal disorder which leads to irreversible vision loss. The main root cause of this disorder is hyper tension, which affects the optic nerves in retinal image. In this paper, an efficient diagnosis system is proposed for screening the Glaucoma disorder using retinal images of the patients. The Optic Disc (OD) and Optic Cup (OC) are segmented from retinal image and further Neuro retinal rim region is detected. The features such as Effective Local Binary Pattern (ELBP), Grey Level Cooccurrence Matrix (GLCM) and Optic Band features are extracted from this neuro retinal rim region. These features are trained and classified using Support Vector Machine (SVM) classifier.

Keywords: Glaucoma, Optic Disc, Optic Cup, features, retinal images.

INTRODUCTION

Diabetic Retinopathy (DR) and Glaucoma are two irreversible disorders related with human retina. DR is caused by diabetes of the patients and the diabetic patients may or may not have the Glaucoma disorder. Screening both retinal disorders are important to prevent earlier vision loss. The number of ophthalmologists required for evaluation by direct examination becomes a limiting factor due to ageing, population growth, physical inactivity and obesity which contributes to increase the risk of vision loss. However, in large-scale screening scenario, these manual assessments are not precise, mostly in developing countries due to the insufficiency of trained experts and scarce modern imaging equipments. Hence, an automatic recognition system which automatically identifies the characteristics of these pathological disorders may be of great advantage for the disease identification. Glaucoma is the primary cause for

blindness and the detection of glaucoma is essential in preventing visual loss. This vision loss disease can be caused by either diabetes or hyper tension. Glaucoma is a complication occurring in the eye leading to blurred or reduced capability of vision in diabetic or hypertension patients. Detection of Glaucoma minor indications is very indispensable as Glaucoma can occur without any major known symptoms.

At once the disease is detected through retinal examinations; immediate treatment is essential which includes laser surgery, glycemic and blood pressure control to prevent the earlier vision loss. Glaucoma can be identified by detecting the optic cup (OC) and optic disc (OD) from the retinal image and analyzing the rim area between OC and OD in the retina. OD is the brightest or higher intensity pixel region especially in the shape of circle in the retinal fundus photographs. Optic cup is the inner circular bright region of optic disc.

The area between the OD and OC is necessary to diagnose glaucoma disease. Due to diabetes or hypertension, the neuro rim between optic cup and optic disc are either swelled or shrunken. By analyzing the swelling or shrinking of neuro rim in retina, the glaucoma disease is diagnosed. The severity of glaucoma is assessed depending on cup to disc ratio (CDR), which is the ratio of the optic cup, optic disc and neuro retinal rim surface areas in retinal image. CDR is an important structural indicator for evaluating the occurrence of the disease and its progression. Fig.1 shows the retinal image affected by Glaucoma disorder. The retinal blood vessels originated from the center of the optic disc are severely affected by its nature.

The organization of this paper is as follows. Section 2 details about various conventional techniques for Glaucoma detection and diagnosis. Section 3 proposes a novel methodology for Glaucoma detection using cup-to-disc ratio. Section 4 discusses the experimental results. Section 5 depicts the conclusion of this paper.

Literature Survey

Ahmed Almazroa *et al* (2015) proposed cup to disc ratio based Glaucoma detection methodology using the segmentation of OD and OC from the retinal image. The authors compared various methodologies for OD and OC screening for Glaucoma detection and diagnosis process. Srinivasan Aruchamy *et al.* (2015) used circular Hough Transform to detect and localize the optic nerve head center in retinal images. The authors achieved an average OD segmentation accuracy of 97.5% for the retinal images available in publicly available dataset. The authors tested their proposed segmentation and Glaucoma classification algorithms on DSP processor to analyze its time consumption. Kurnika Choudhary *et al.* (2015) used artificial neural network for the detection and classification of Glaucoma disorder in diabetic patients. The authors used feed forward back propagation neural network for training and testing the retinal images for Glaucoma classifications. Prasad N. Maldhure *et al.* (2015) used the technique of OD and OC segmentation for Glaucoma detection and diagnosis process. The super pixel

classification approach was used to segment the OD and OC regions in retinal images. The severity of Glaucoma was classified based on Cup to disc ratio. The authors achieved 96% of average Optic disc segmentation for Glaucoma detection.

G. Jayanthi *et al.* (2014) proposed Glaucoma screening technique on retinal images using level set approach. This method failed to give the optimum result on high resolution retinal images. The authors achieved average precision of 90% and Recall parameter of 96.6% for the optic disc segmentation in low resolution retinal images. Muthu Rama Krishnan *et al.* (2013) used trace transform for Glaucoma detection in retinal images. The Discrete Wavelet features were extracted from the retinal image and SVM classifier was used to train and classify these features. The authors achieved 91.67% as average classification accuracy for Glaucoma disorder classifications.

MATERIALS AND METHODS

Materials

In this paper, the publicly available dataset HRF (High Resolution Fundus) is used to detect and diagnose Glaucoma disorder [14]. This dataset contains 45 retinal images, where 15 are categorized into normal and where 15 are categorized into DR images and where 15 images are categorized into Glaucoma images. In this paper, 15 images from both normal and Glaucoma retinal images are considered. Each retinal image was taken with a Canon CR-1 fundus camera with a field of view of 45° and different acquisition setting. This dataset also contains Ground truth or Gold standard images for OD segmentation by expert Ophthalmologist.

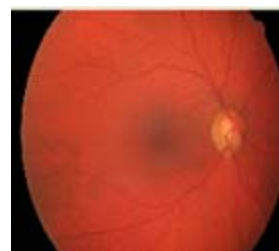


Fig. 1: Glaucoma Retinal Image

Methods

The proposed methodology for Glaucoma detection using retinal images in training and Classification mode are shown in Fig.2 and Fig.3, respectively. This proposed method consists of OD and OC segmentation using Morphological operations, Neuro retinal rim detection, Feature extraction and Classification.

Fig.2 details the training mode of the SVM classifier which extracts and trains the features from both healthy and Glaucoma retinal images in HRF dataset. Fig.3 details the classification mode of the SVM classifier which extracts and classifies the features from test retinal image into either normal or abnormal. The healthy retinal images are categorized as normal and Glaucoma retinal images are categorized as abnormal.

OD segmentation

The OD region in retinal image as shown in Fig.4 (a) has the lower intensity pixels than the

pixels in OC region. The OD and OC regions are extracted using binary mathematical morphology operations as follows. Initially, the retinal RGB image is separated into red, green and blue channels. The OD region is clearly visible in Red channel image[15] as shown in Fig.4 (b) and hence it is further used for OD and OC region extraction. The morphologically closing function with disc shaped structuring element 10 (pixels) is now applied on the red channel image and further morphologically opening function with disc shaped structuring element 20 (pixels) is applied on the same red channel image. The morphologically closed and opened image is shown in Figure 4 (c) and Figure 4 (d).

Now, the absolute subtraction is performed between morphologically closed and opened images and the subtracted image will clearly shows the OD region which is shown in Figure 5a and its is overlaid on the retinal RGB image as shown in Fig.5b.

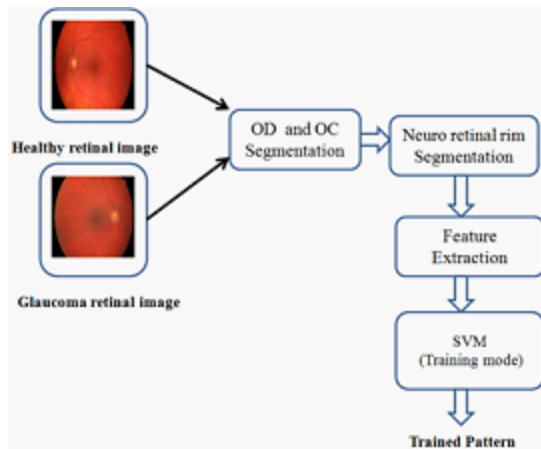


Fig. 2: Glaucoma detectionsystem in Training mode

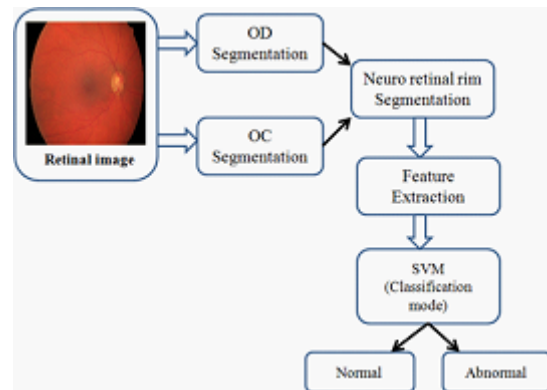


Fig. 3: Glaucoma detectionsystem in Classification mode

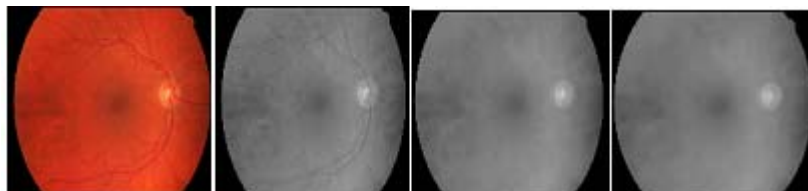


Fig. 4: (a) Retinal Image (b) Red channel image (c) Morphological closed image (d) Morphological opened image

OC Segmentation

The OC region has higher intensity pixels than the OD region pixels and located inside the OD region as shown in Fig.6 (a). The segmentation of OC is a difficult task due to its boundary between OD and OC region. The Red channel is separated from RGB retinal image, which also shows the OC clearly. The independent component analysis method [10] has been employed on this red channel image to locate the OC region pixels with some redundant pixels. Next, the morphological opening function is applied on this image in order to remove the redundant pixels and locate the OC pixels exactly as shown in Fig.6 (b). Finally, the binary

image is constructed from this morphologically processed image. The pixels with white in color are marked as OC pixels in the RGB retinal image. The OC segmented image is now subtracted from OD segmented image to extract the rim area as shown in Fig.6 (c) between OD and OC and it is further used for glaucoma severity classifications.

Feature Extraction

Features are the characteristics of the object which is used to differentiate one object from another object using its properties as morphological and texture. In this paper, Enhanced Local Binary Pattern (ELBP) and Grey Level Co-occurrence

Table 1: Optic Disc Segmentation Results

Image	Se	Sp	Ppv	Npv	Acc	Pr	FPR	FNR	LPR	LNR
1	81.60	98.96	80.41	99.76	98.74	50.41	1.04	18.40	7841.65	18.59
2	46.07	99.97	95.11	99.28	99.16	95.11	0.03	53.93	145290.73	53.95
3	73.34	99.95	96.53	99.52	99.48	96.53	0.05	26.66	154692.34	26.67
4	82.25	99.72	81.51	99.73	99.46	81.51	0.28	17.75	29266.43	17.80
5	65.17	99.82	83.44	99.53	99.36	83.44	0.18	34.83	37187.97	34.89
6	39.65	99.99	98.73	99.11	99.11	98.73	0.01	60.35	523320.18	60.36
7	99.17	99.45	72.09	99.99	99.44	72.09	0.55	0.83	17883.81	0.84
8	84.97	99.75	82.70	99.79	99.54	82.70	0.25	15.03	33457.09	15.07
9	64.90	99.81	81.26	99.57	99.39	81.26	0.19	35.10	34985.91	35.17
10	65.47	99.77	79.15	99.55	99.33	79.15	0.23	34.53	28964.76	34.61
Average	70.25	99.71	85.09	99.58	99.30	82.09	0.281	29.73	101289.08	29.79

Table 2: Optic band features from Neuro retinal rim area

Images	OB _t	OB _b	OB _l	OB _r
1	1166	1038	1128	775
2	502	558	552	511
3	923	735	1120	680
4	1114	981	690	1042
5	894	1004	750	899
6	409	399	314	320
7	1481	1067	1785	1083
8	842	962	652	1145
9	587	655	550	649
10	921	788	699	783

OB_t= Optic band top; OB_b= Optic band bottom;
OB_l= Optic band left; OB_r=Optic band right

Matrix (GLCM) features are extracted from the neuro retinal rim region and these extracted features are given as input to SVM classifier. The ELBP feature is given as,

$$ELBP = \sum_{p=1}^8 2^p * M(I_N - I_C) \quad \dots(1)$$

Table 3 : Performance comparison of the OD segmentation in HRF dataset

Methodologies	Year	Accuracy (%)
Proposed work	2016	99.30
Koprowski <i>et al</i> [6]	2014	86.0
Kavitha <i>et al</i> [8]	2013	93.5
Muthu Rama	2012	93.4
Krishnan <i>et al</i> [9]		

where, I_N denotes the neighboring pixel in a square window (3x3), I_C is the center pixel in the square window, 'p' denotes number of neighboring pixels around center pixel noted as 8 in 3x3 square window, 'M' denotes specific function and $M(I_N - I_C)$ is marked as the threshold value and it is estimated

$$M(I_N - I_C) = \begin{cases} 1, & \text{if } I_N - I_C \geq 0 \\ 0, & \text{if } I_N - I_C < 0 \end{cases} \quad \dots(2)$$

The features Energy, correlation, homogeneity and contrast are used as GLCM features which are extracted from Neuro retinal rim region.

Optic Band features are also extracted from the neuro retinal image. The segmented neuro retinal rim region is divided into top band, bottom band, left band and right band. These four extracted bands are used

Classification

In this paper, SVM classifier is used for the classification of extracted feature patterns from neuro retinal rim region from both healthy and Glaucoma retinal images. In training mode of the SVM classifier, the features are extracted from both healthy and Glaucoma retinal images which are obtained from HRF open access dataset to derive the trained pattern. This trained pattern consists of feature patterns of both healthy and Glaucoma cases. In classification mode of the SVM classifier,

the features from test retinal image is compared with the trained feature pattern to classify the test retinal image into either healthy or Glaucoma retinal image.

RESULTS AND DISCUSSION

The proposed optic disc and cup segmentation algorithm have been applied for a set of images available in HRF database and the segmentation results were compared with their respective ground truth images given by specialized ophthalmologists. The performance parameters obtained after the segmentation of optic disc and optic cup region for a few set of images are tabulated and is given in Table 1. To measure the performance of the proposed method in detecting the optic cup and optic disc region on the fundus image, the proposed segmentation method is compared to its corresponding ground truth images. The ground truth fundus images used for our experimentation were obtained from the publicly available HRF database. The performance of optic disc segmentation is analyzed with the following parameters:

- Sensitivity (Se=TP/(TP+FN))
- Specificity (Sp=TN / (TN+FP))
- Positive predictive value (Ppv=TP / (TP+FP))
- Negative predictive value (Npv=TN / (TN+FN))
- Accuracy (Acc=(TP+TN) / (TP+FN+TN+FP))
- Precision=TP / (TP+FP)
- False positive rate (FPR)=FP / (FP+TN)
- False negative rate (FNR)=FN / (TP+FN)
- Likelihood ratio positive (LPR)=Sensitivity / (1-Specificity)
- Likelihood ratio negative (LNR)=(1-Sensitivity) / Specificity

These performance parameters are evaluated and listed in Table 1, where, TP denotes

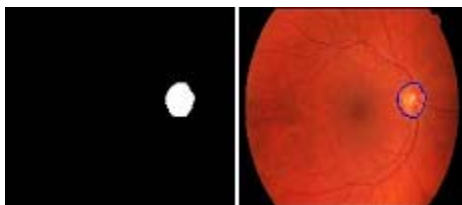


Fig. 5: (a) Binary image (b) OD segmented image



Fig. 6: (a) Segmented OD (b) Segmented OC (c) Neuro retinal rim region



Fig. 7: (a) Optic band top (b) Optic band bottom (c) Optic band left (d) Optic band right

true positive, FP denotes false positive, FN is false negative and TN is true negative. True Positive refers to the correctly identified optic disc pixels, True Negative refers to the wrongly identified optic disc pixels, False Positive refers to the correctly identified background pixels and False Negative refers to the wrongly identified background pixels. The entire algorithm was run on the HRF database and results for optic disk and optic cup detection and segmentations were obtained. The MATLAB code takes 9 seconds per image on an average to run on a 2.1 GHz Intel Pentium Corei3 machine with 4GB of RAM.

The proposed methodology for OD segmentation provides 70.25% sensitivity, 99.71% specificity and 99.30% accuracy. Table 2 shows the extracted optic band features from neuro retinal rim region.

Table 3 shows the performance comparisons of the proposed OD segmentation methodology with conventional methodologies as Koprowski *et al* (2014), Kavitha *et al* (2013) and Muthu *et al* (2012). The proposed OD segmentation methodology achieves 99.3% average accuracy while the conventional methodology Koprowski *et al* (2014) achieves 86% of an average accuracy, Kavitha *et al* (2013) achieves 93.5% of an average accuracy and Muthu *et al* (2012) achieves 93.4% of an average accuracy for OD segmentation. The reason behind the

proposed OD segmentation methodology is that it detects and segments inner and outer boundary of the OD region more accurately when compared with other conventional techniques for OD segmentation. This proposed OD segmentation methodology also provides low and high resolution retinal images.

CONCLUSION

In this paper, an automated efficient system for screening Glaucoma disorder is proposed through the segmentation of optic disc and optic cup region in retinal images. The optic disc and optic cup regions are segmented using Morphological operations as erosion followed by dilation. The features are extracted from neuro retinal rim region and these features are trained and classified using SVM classifier. The proposed OD segmentation methodology achieves 99.3% average accuracy while the conventional methodologies.

ACKNOWLEDGEMENT

In this moment I would like to thank the institution National Engineering College and MEPCO Schlenk Engineering College for providing me the facilities to carry out this research work. I also extend my thanks to Head of Department, colleagues, family members and friends for their support and encouragement.

REFERENCES

1. Ahmed Almazroa, Ritambhar Burman, Kaamran Raahemifar, and Vasudevan Lakshminarayanan. Optic Disc and Optic Cup Segmentation Methodologies for Glaucoma Image Detection: A Survey. *Journal of Ophthalmology.*, 1-28 (2015).
2. Srinivasan Aruchamy, Partha Bhattacharjee and Goutam Sanyal. Automated Glaucoma Screening in Retinal Fundus Images. *International Journal of Multimedia and Ubiquitous Engineering.*, 10(9): 129-136 (2015).
3. Kurnika Choudhary and Shamik Tiwari. ANN Glaucoma Detection using Cup-to-Disk Ratio and Neuroretinal Rim. *International Journal of Computer Applications.*, 111(11): 8-14 (2015).
4. Prasad N. Maldhure, V.V.Dixit. Glaucoma Detection Using Optic Cup and Optic Disc Segmentation. *International Journal of Engineering Trends and Technology.*, 20(2): 52-55 ((2015)).
5. G.Jayanthi, G.Mary Amirtha Sagayee, and S.Arumugam. Glaucoma Detection in Retinal Image using Medial Axis Detection and

- Level Set Method. *International Journal of Computer Applications.*, **96**(3): 42-48 (2014).
6. Koprowski, R, Rzendkowski, M and Wrobel, Z. Automatic method of analysis of OCT images in assessing the severity degree of Glaucoma and the visual field loss. *Bio Medical Engineering Online.*, **13**(16): 3-18 (2014).
 7. M Muthu Rama Krishnan and Oliver Faust. Automated Glaucoma Detection Using Hybrid Feature Extraction In Retinal Fundus Images. *J. Mech. Med. Biol.*, **13**(1): 1-21 (2013).
 8. Kavitha, S and Duraiswamy, K. An automatic retinal optic disc segmentation algorithm using differential windowing in the polar coordinate domain. *Australian Journal of Electrical and Electronics Engineering.*, **10**(1): 33-44 (2013).
 9. Muthu Rama Krishnan, M, Chua Kuang Chua and Lim Choo Min. Application of intuitionistic fuzzy histon segmentation for the automated detection of optic disc in digital fundus images. Proceedings of the IEEE-EMBS International Conference on Biomedical and Health Informatics., 444-447 (2012).
 10. Dominic Langlois, Sylvain Chartier, and Dominique Gosselin. An Introduction to Independent Component Analysis InfoMax and FastICA algorithms. *Tutorials in Quantitative Methods for Psychology.*, **6**(1): 31-38 (2010).
 11. Koen A Vermeer, Frans M Vos, Barrick Lo, Qienyuan Zhou, Hans G Lemij, Albert M Vossepoel and Lucas J van Vliet. Modeling of Scanning Laser Polarimetry Images of the Human Retina for Progression Detection of Glaucoma. *IEEE Transactions on Medical Imaging.*, **25**(5): 517-528 (2006).
 12. Kwokleung Chan, Te-Won Lee, Pamela A Sample, Michael H Goldbaum, Robert N Weinreb and Terrence J Sejnowski. Comparison of Machine Learning and Traditional Classifiers in Glaucoma Diagnosis. *IEEE Transactions on Biomedical Engineering.*, **49**(9): 963-974 (2002).
 13. Lalonde, M, Beaulieu, M and Gagnon, L. Fast and robust optic disc detection using pyramidal decomposition and hausdorff-based template matching. *IEEE Transactions on Medical Imaging.*, **20**(11): 1193-1200 (2011).
 14. Thomas Köhler, Attila Budai, Martin Kraus, Jan Odstrcilik, Georg Michelson, Joachim Hornegger. Automatic No-Reference Quality Assessment for Retinal Fundus Images Using Vessel Segmentation. 26th IEEE International Symposium on Computer-Based Medical Systems., 2013;
 15. Nur Ayuni Mohamed, Mohd Asyraf Zulkifley, Aini Hussain, Aouache Mustapha. Local Binary Patterns and Modified Red Channel for Optic Disc Segmentation. *Journal of Theoretical and Applied Information Technology.*, **81**(1): 84-91 (2015).