

## Stevens-johnson syndrome and toxic epidermal necrolysis in a nigerian Mother and Child

O.A. ONI<sup>1</sup>, P.O. OTUAGA<sup>2</sup>, L.E. EBITE<sup>2</sup>, T.C. OZOKO<sup>3</sup> and O. AGHIMIEN<sup>4</sup>

<sup>1</sup>Consultant Physician, Niger Delta University Wilberforce Island, Amassoma Bayelsa State

<sup>2</sup>Department of Anatomy, School of Basic Medical Sciences, College of health Sciences, Delta State University, Abraka, Delta State.

<sup>3</sup>Lecturer, Department of Medical Microbiology and Parasitology College of Health Sciences Delta State University, Abraka

<sup>4</sup>Department of Pharmacy, UBTH, Benin City, Edo State.

(Received: May 30, 2008; Accepted: July 06, 2008)

### ABSTRACT

Stevens-Johnson syndrome(SJS) and Toxic epidermal necrolysis(TEN) are idiosyncratic immune complex mediated hypersensitivity reaction.Cytotoxic Hypersensitivity reaction has also be implicated especially in TEN which is a severe form of stevens- Johnson syndrome.In this article,we report a 13year old boy who was treated for a febrile ailment with a mixture of ampicillin and cotrimoxazole by his mother who also tasted the drug.Two weeks later,the child developed fever,sour throat,itching of the body,abdominal pain and later sloughing of the skin and mucous membrane of the mouth and nasal cavity.There was also conjunctivitis, dysphagia and dysuria.In addition,his mother presented with conjunctivitis,Sloughing of the oral mucosa and vaginal with few bullae around the vaginal orifice.The patients had mortality rates of 58.3% and 12.1% for the child and mother respectively(Severity of illness score).Both patients were admitted with the diagnosis of Stevens-Johnson syndrome(Mother) and Toxic epidermal necrolysis(Child).The offending drugs(ampicillin and cotrimoxazole) were withdrawn immediately after admission.Both patients survived and were discharged after vigorous treatment with tabs prednisolone, rehydration(IV normal saline),IV ciprofloxacin and gentamycin ointment.In addition,the patient who had toxic epidermal necrolysis was given Intra muscular injections of tetanus toxoid 0.5ml.

**Key words:** Stevens-Johnson syndrome, Toxic epidermal necrolysis, idiosyncratic, cotrimoxazole, ampicillin.

### INTRODUCTION

Stevens-Johnson syndrome (SJS) was first described in 1922 as an immune complex-mediated hypersensitivity reaction also known by some authors as erythema multiforme major<sup>1</sup>. Alan Lyell described toxic epidermal necrolysis(TEN) in 1956 as an eruption resembling scalding of the skin<sup>1</sup>.TEN is characterized by extensive epidermal loss suggestive of severe scalding<sup>1</sup>.Most authors and experts consider SJS and TEN as different manifestations of the same disease process. Hence,

many refer to the entity as SJS/TEN.Mucous membrane involvement may lead to necrosis with potential for severe morbidity.Missed diagnosis is not uncommon as many conditions like staphylococcal scalded skin disease may mimic SJS/TEN. The simplest classification scheme divides the disease into three:

\*SJS - A minor form of TEN with less than 10% body surface area (BSA) detachment.

\*Overlapping SJS/TEN – Detachment of 10-30% BSA

\* TEN- Detachment of more than 30% BSA(2).

There is usually a 1-14 day prodrome during which systemic symptoms are present. The pathophysiology involves an immune complex hypersensitivity disorder that may be caused commonly by drugs like sulphonamides, penicillins, antiepileptics, viral infections and malignancies<sup>2,3</sup>. In 50% of cases, no specific etiology has been identified<sup>2,3</sup>. Pathologically, there is cell death causing the separation of the epidermis from the dermis. Inflammatory cytokines, death receptor, fas and its ligand (fasL) have been linked to the process. In the Niger Delta (Bayelsa) the prevalence rate is 0.67% (4). Worldwide, the average incidence is 0.5-1.4 cases per million population per year<sup>5</sup>. The mortality and morbidity is estimated to be 10-70% depending on the quality and rapidity of treatment<sup>5</sup>.

Lesions may erupt in crops for as long as 2-3 weeks. There may be mucosa scarring and loss of function of the organ system. In severe cases there is esophageal stricture, respiratory symptoms and failure, panophthalmitis, vaginal stenosis, penile scarring. Mortality risk depends on the prognostic factors according to the TEN specific severity of illness score (SCORTEN). Each factor is given a score of 1

- Age >40 years
- Malignancy
- Heart rate > 120
- Epidermal detachment > 10%
- BUN level > 10mmol/L
- Serum glucose level >14mmol/L
- Bicarbonate level <20mmol/L

**Mortality rates therefore are as follows:**

SCORTEN 0-1 ≥3.2%

SCORTEN 2 ≥12.1%

SCORTEN 3 ≥35.3%

SCORTEN 4 ≥58.3%

SCORTEN 5 or more ≥90% (6)

SJS/TEN occur in all age groups and for unclear reasons, females have a greater predilection for developing TEN than their male counterpart<sup>7,8</sup>. Diagnosis is made with the clinical features and skin biopsy (Subepidermal bullae). Full blood count (FBC) may be normal but a severely elevated white cell count indicates the possibility of a superimposed bacterial infection. There might be a raised urea level

and blood in urine. Blood, urine and swab culture should be done if there is a suspected infection.

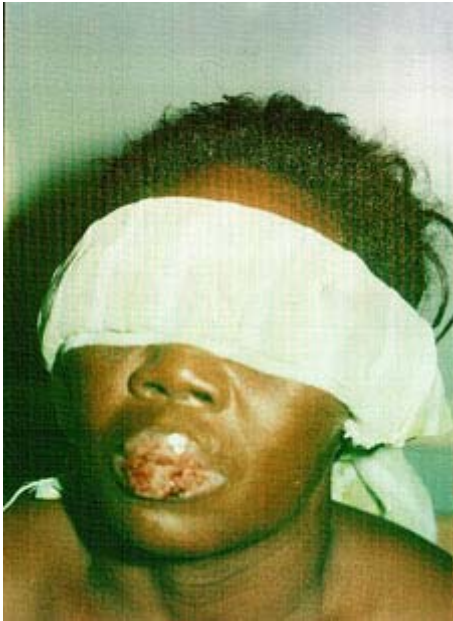Treatment involves admitting patients and withdrawal of offending agent. There must be adequate fluid replacement and electrolyte correction. Attention should be given to treatment with topical antibiotics (not containing offending drug) and control of pain with analgesics. Some researchers have advocated the use of cyclophosphamide, plasmapheresis and hemodialysis<sup>9,10</sup>. Corticosteroids are indicated in early disease. Oral lesions are managed with mouth wash and tetanus prophylaxis is indicated in severe skin involvement. Areas of denuded skin should be covered with saline compress and severe cases may require the involvement of burns specialist, plastic surgeons, ophthalmologist, physicians and paediatricians. The choice of antibiotics depends on the result of microscopy culture and sensitivity. High doses of systemic steroids are vital in the early stages when new eruptions are evident. Human intravenous immunoglobulin has been described as treatment and prophylaxis<sup>11,12</sup>. Other causes must be addressed and treated appropriately. Patients must avoid any future exposure to agents implicated in the occurrence of SJS or TEN.

**Case presentation**


We present a child and his mother who ingested a mixture of ampicillin and cotrimoxazole bought in a chemist for a febrile ailment. Mother only tested the mixture before given her child to ingest. Two weeks after ingestion of the antibiotics mixture, the child started having systemic symptoms of cough, fever, chills, malaise, headache followed by an abrupt eruption of blisters. The mucous membranes of the eyes, nose, mouth and anal region were affected. The child presented with 100% skin necrosis and sloughing and was febrile to touch ( $T \geq 39^\circ\text{C}$ ). However, his mother presented with fever, evidence of conjunctivitis and necrosis of the oral and vaginal mucous membranes. Both presented with difficulty in swallowing, breathlessness, and eye pain. There was slight raised urea level and hypokalaemia in the child. FBC revealed marked leucocytosis in both patients who were adequately rehydrated with normal saline. They were given IV Ciprofloxacin, topical gentamycin ointment and saline compression applied to the

denuded areas of the skin. Mother was given 60mg of prednisolone (high dose) while baby had 30mg daily for the first one week before reducing the doses respectively. Two weeks later, mother's condition improved satisfactorily and she was discharged home for follow up management in the clinic. This

case is presented due to the increase rate of drug misuse including antibiotics which may lead to death from severe drug reaction especially in the rural areas of Bayelsa state and the Niger Delta region of Nigeria.



**Fig. 1: Mother with SJS**



**Fig. 2: Child with TEN**

## DISCUSSION

SJS and TEN are immune complex mediated hypersensitivity disorder that may be caused by drugs, viral infections and malignancies. Drugs are commonest causes and ampicillin and sulphure containing drugs are priority causes of SJS/TEN. These are the causes of the cases under review. Cohen et al in his work on SJS/TEN stated that both diseases have been considered to be different manifestations of the same disease process(2). He added that patients with Stevens-Johnson syndrome normally have mucous membrane involvement and may have few or no bullae(2). The two cases presented in figures 1 and 2 are in line with his work. Both patients swallowed the same drugs but different quantity. The child who

was on treatment with ampicillin and cotrimoxazole presented with TEN while her mother who administered the drugs presented with Stevens-Johnson syndrome. The patient with Stevens-Johnson syndrome had very few bullae (3-4) around the vaginal. However, there were severe mucous membrane involvement of the eyes, nose, oralpharynx, vaginal and urethral orifice. Hence, the diagnosis of SJS can still be made without marked bullous skin eruption. Nikolsky sign is usually positive in SJS with marked skin involvement and TEN(13). This was evident on lateral pressure to the epidermis of our patient with TEN. In the management of TEN and SJS, many believed that steroid use is contra-indicated because it may predispose to infections, mask early signs of sepsis, encourage gastrointestinal bleeding and delay

wound healing(14). But these were not evident in our patients who improved remarkably on high dose steroids. The use of steroids in SJS and TEN cannot be overemphasized as an anti-inflammatory agent in the active erupting stage of both diseases. Complications develop if steroid use exceeds the active phase of bullae formation. Infections which may arise from long use of steroids and super infection of the exposed areas of the epidermis are treated with antibiotics that are rare causes of SJS/TEN(15,16). Using the scorten scores to evaluate the mortality rate, the patient with SJS had a mortality of 12.1% while her

child had a mortality of 58.3%. However, it is interesting to state that both patients survived without complications. In conclusion, SJS/TEN are immune hypersensitivity reactions that can be treated if they present early. Steroids are still very useful and needed in the early active stage of both diseases and antibiotics are equally important. Team management is of immense benefit to patients with SJS and TEN. Finally, there is need for proper education of the citizens /patients in order to avert use of unprescribed drugs and patronage of drug hawkers and patent medicine store dealers without expert consultation.

## REFERENCES

1. French LE. TEN and SJS. Our current understanding. *Allergol Int* **55**(1): 9-16 (2006).
2. Cohen B. The many faces of erythema multiforme. *Contemp Pediatr*; **11**: 19-39 (1994).
3. Parrillo SJ. SJS and TEN. *Curr Allergy Asthma Rep* **7**(4): 243-7 (2007).
4. Medical Record, NDUTH, Okolobiri (2008).
5. Cohen V, Samantha PJ, Robert AS. TEN. *Medscape J*; **1**: 1-11. (<http://www.emedicine.com/med/topic2291.htm>) (2006).
6. Bastuji GS, Fouchard N, Bertocchi M. Scorten a severity of illness score for TEN. *J Invest Dermatol* **115**(2): 149-153 (2000).
7. Sharma VK, Dhar S. Clinical pattern of cutaneous drug eruption among children and adolescents in north India. *Pediatr Dermatol* **12**(2): 178-83 (1995).
8. Chave TA, Mortimer NJ, Sladden MJ. TEN, current evidence, practical management and future directions. *Br J Dermatol* **153**(2): 241-53 (2005).
9. Schwartz RA, Dmochowski M. The erythema multiforme spectrum. Pathogenesis, pathology and links with the pemphigus spectrum. *Postepy Dermatol* **15**: 7-23 (1998).
10. Paquet P, Pierard GE, Quatresooz P. Novel treatments for drug induced TEN (Lyell's syndrome). *Int Arch Allergy Immunol.*, **136**(3): 205-16 (2005).
11. Letko E, Papaliodis DN, Papaliodis GN. SJS and TEN. A review of the literature. *Ann Allergy Asthma Immunol* **94**(4): 419-36 (2005).
12. Revuz J. New advances in severe adverse drug reactions. *Dermatol Clin* **19**(4): 697-709 (2001).
13. Salopek TG. Nikolsky's sign. Is it dry or wet. *Br J Dermatol* **136**(5): 762-7 (1997).
14. Sane SP, Bhatt AD. SJS and TEN challenges of recognition and management. *J Assoc Physicians India* **48**(10): 999-1003 (2000).
15. Garcia DI, Le Cleach L, Bocquet H. TEN and SJS. Does early withdrawal of causative drugs decrease the risk of death? *Arch Dermatol.*, **136**(3): 323-7 (2000).
16. Cunha BA. Antibiotics side effects. *Med Clin North Am* **85**(1): 149-85 (2001).